



Distant metastases from the uterine leiomyoma – case report of a pulmonary benign metastasizing leiomyoma

Natalia Izabela Szczęsny^{1,A-D,F}, Karolina Karoń^{2,A-D}, Ewelina Bornio^{2,A-D},
Krzysztof Piątkowski^{2,A-D}, Wojciech Grabowski^{2,B,D}, Hanna Plata^{1,A}, Szymon Piątek^{3,E-F}

¹ Department of Clinical Interventional Sciences, Faculty of Medical Sciences and Health Sciences, Kazimierz Pułaski University, Radom, Poland

² Student Scientific Association, Department of Gynaecologic Oncology, Maria Skłodowska-Curie National Institute of Oncology – National Research Institute, Warsaw, Poland

³ Gynaecologic Oncology Clinic, Maria Skłodowska-Curie National Institute of Oncology – National Research Institute, Warsaw, Poland

A – Research concept and design, B – Collection and/or assembly of data, C – Data analysis and interpretation, D – Writing the article, E – Critical revision of the article, F – Final approval of the article

Szczęsny NI, Karoń K, Bornio E, Piątkowski K, Grabowski W, Plata H, Piątek Sz. Distant metastases from the uterine leiomyoma: a case report of a pulmonary benign metastasizing leiomyoma. *J Pre-Clin Clin Res.* 2024; 18(3): 213–217. doi: 10.26444/jpccr/190538

Abstract

Benign metastasizing leiomyoma (BML) is a rare condition predominantly affecting women of late reproductive age, characterized by metastasis of the uterine leiomyomas to distant organs. The case is presented of a 48-year-old woman with BML who initially presented with non-specific abdominal pain. She was diagnosed with a uterine tumour and multiple pulmonary metastases. Therefore, uterine sarcoma was suspected. However, pathologic examination of core needle biopsy of the uterine tumour revealed leiomyoma cells. Due to inconsistency between pathologic examination and imaging, hysterectomy was performed. The final pathologic diagnosis confirmed leiomyoma in the uterus. To exclude another malignancy, thoracotomy with open lung biopsy was performed. Histopathological examination showed the same cells as in the uterine leiomyoma, resulting in the diagnosis of BML. Gonadotropin-releasing hormone (GnRH) analog was administered. After 15 months, the patient remained stable without disease progression.

Key words

uterine leiomyoma, pulmonary metastases, benign metastasizing leiomyoma (BML)

INTRODUCTION

Benign metastasizing leiomyoma (BML) is a rare benign tumour, which predominantly occurs in women with a previous history of uterine leiomyomas. The average age at the moment of BML diagnosis is 47.3 years [1]. Although uterine leiomyomas are the most common benign neoplasms of the female reproductive system, their metastases to distant organs are exceptionally uncommon. The etiology and mechanism of metastasis are not fully clarified. One proposed etiological hypothesis declares that the ‘metastases’ arise from localized smooth muscle proliferation within the affected organs. Alternatively, another hypothesis suggests that BML may manifest as a low-grade leiomyosarcoma. A third theory proposes the haematogenous dissemination of the primary lesion as the underlying mechanism [2].

Pulmonary benign metastasizing leiomyoma (PBML) appears as the most frequent site of metastases, whereas exceedingly rare cases involve metastasis to the heart, duodenum, appendix, and parametria [2–4]. The vast majority of BML cases are asymptomatic, posing challenges in timely diagnosis [5]. Symptoms of BML are related to the site of metastasis and advancement of the disease. They

include cough, haemoptysis, anaemia, dyspnea, decreased pulmonary function, and even pneumothorax [6,7]. Diagnostics rely primarily on histopathological assessment through biopsy of suspicious lesions. Additionally, positron emission tomography-computed tomography (PET-CT) and computed tomography (CT) play crucial roles in the diagnostic algorithm [8].

Microscopically, BML does not show features of malignancy and demonstrates similarity to uterine leiomyoma [5]. Smooth muscle differentiation can be confirmed by positive immunohistochemical tests for desmin and smooth muscle actin [8]. On imaging, it presents as multiple, well-demarcated lesions with a diameter of up to 4 cm [5]. The primary therapeutic approach for BML typically involves hysterectomy. Gonadotropin-releasing hormone (GnRH) analogs, specifically ulipristal acetate, represent the exclusive non-invasive systemic treatment option currently available for BML management [7,9]. Treatment and prognosis of BML have not been established due to the rarity of the disease and the limited number of cases. The case is presented of a BML with metastases to the lungs.

CASE REPORT

A 48-year-old nulliparous woman with anaemia, increased abdominal circumference, reduced appetite, nausea, and vomiting was referred to the Department of Gynaecologic

✉ Address for correspondence: Natalia Izabela Szczęsny, Department of Clinical Interventional Sciences, Faculty of Medical Sciences and Health Sciences, Casimir Pulaski Radom University, Radom, Poland
E-mail: Natalia.szczesny@gmail.com

Received: 05.05.2024; accepted: 27.06.2024; first published: 19.07.2024

Oncology at the Maria Skłodowska-Curie National Research Institute of Oncology in Warsaw, Poland, due to a tumour filling the abdominal cavity. She had no history of smoking tobacco or marijuana, and was not receiving regular medical care due to her low socio-economic status. The patient had a medical history of epilepsy, likely resulting from cranial trepanation due to a traffic accident in childhood. She also had a history of hepatitis B virus (HBV) infection.

Upon physical examination, a palpable tumour filled the whole abdominal cavity. The mass bilaterally compressed the ureters leading to an elevated serum creatinine level of 2.5 mg/dl. Computed tomography (CT) of the chest, abdomen, and pelvis (conducted without contrast due to abnormal renal parameters) revealed multiple lesions in the lungs and irregular, heterogeneous uterine mass in the abdominal and pelvic regions. Notably, the dimensions of the tumour were 307 × 225 × 302 mm, with a solid area exhibiting small calcifications (Fig. 1). Additionally, a cystic lesion was found adjacent to the left kidney. Serum biomarkers levels were within the normal range: Ca-125 21.3 U/ml, Ca 19-9 23.3 U/ml, and CEA 1.39 ng/ml.

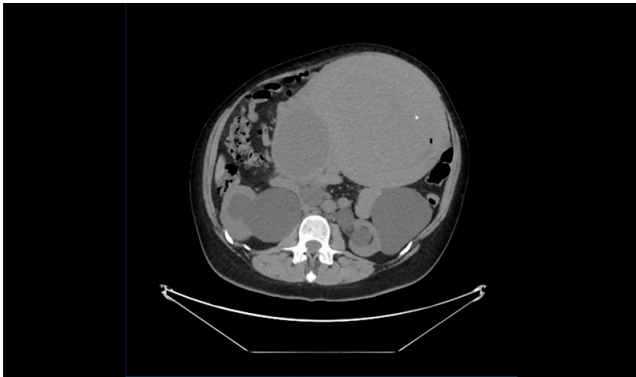


Figure 1. Pathological litho-cystic mass with dimensions of 307 × 225 × 302 mm

The patient underwent a bilateral nephrostomy, which led to the normalization of renal function. The contrast CT confirmed numerous metastases in the lungs (Fig. 2A, 2B), reaching sizes of up to 48 mm, together with the identification of emphysematous bullae, with the largest measuring 72 mm in the left lung. No enlarged lymph nodes were found in the chest. In the abdominal and pelvic regions, apart from the large uterine tumour, a solitary satellite lesion measuring 30 mm, located at the ascending colon, was noted. Peri-aortic lymph nodes showed diameters of up to 12 mm. No pathological findings were noticeable in the liver, gallbladder, pancreas, adrenal glands, or bladder. Skeletal assessments revealed the absence of metastases.

Due to the suspicion of uterine sarcoma, the patient underwent a core-needle biopsy of the abdominal mass. Histopathological examination revealed a mesenchymal tumour component characterized by heightened cellularity, devoid of significant atypia or mitotic activity. Immunophenotyping revealed positive expression of smooth muscle actin (SMA), caldesmon (CALDES), CD10, progesterone receptor (PR), estrogen receptor (ER), desmin (DES), and cyclin D1 (CYCLD1), with low expression of p16 and a low mitotic index (Ki-67 less than 2%). Immunostaining for S100 was negative, and p53 exhibited a wild-type expression pattern. These histological and immunophenotypic findings suggested a diagnosis of cellular leiomyoma.

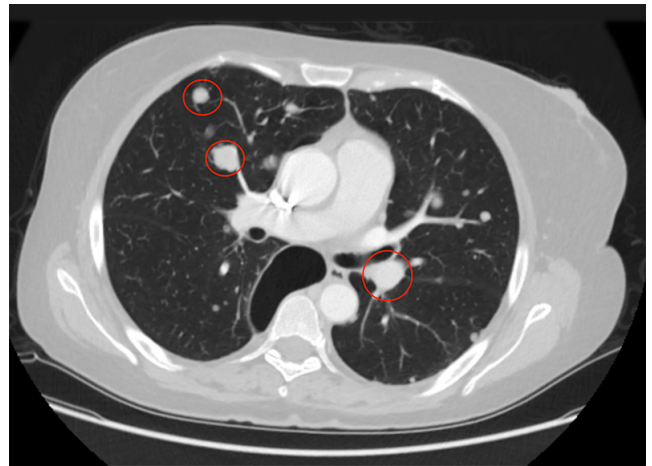


Figure 2A. Numerous metastatic foci in the lungs

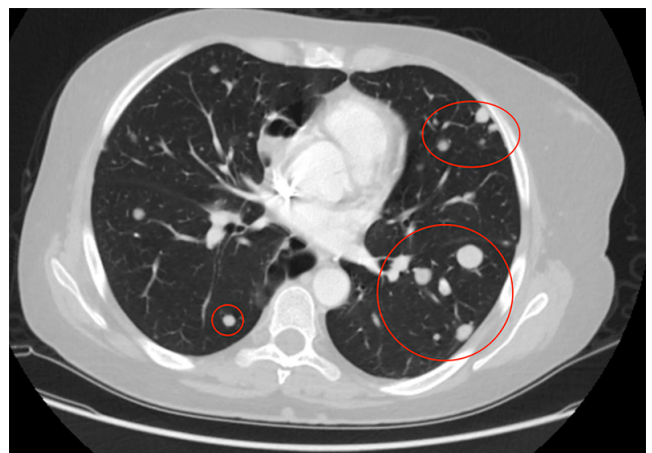

Figure 2B. Numerous metastatic foci in the lungs

Due to a discrepancy between clinical, radiological, and histopathological assessments, she was scheduled for definitive surgical management. The patient underwent a hysterectomy with bilateral salpingo-oophorectomy and resection of tumour lesions from the retroperitoneal space. Surgery was complicated by bilateral transection of the ureters and urinary bladder. These complications were adequately treated.

The post-surgical period was complicated by intraperitoneal haemorrhage. The haemoglobin level dropped to 5.5 g/dl and the patient underwent immediate relaparotomy. Following management in an intensive care unit (ICU), a marked improvement in the patient's clinical status was observed, with stabilization of circulatory and respiratory parameters.

A subsequent follow-up CT scan showed reduced metastatic lesions in the lungs (compared to 4 months prior to surgery), and no residual tumour in the abdomen (Fig. 3). The result of the post-operative histopathological examination confirmed the diagnosis of leiomyoma, ruling out, unequivocally, the original presumption of uterine sarcoma. Therefore, it was decided to identify the lung lesions in order to determine whether they might be metastases of another malignancy. The patient was qualified for thoracic surgery. An open biopsy of the right lung was performed, the emphysematous bullae was resected and a section of the lower and middle lobes with lesions was excised. The histopathological result of the lung biopsy revealed findings consistent with BML. GnRH analog was used as adjuvant treatment.

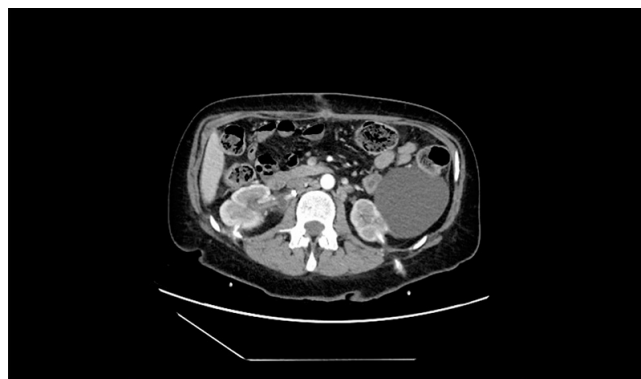

Figure 3. Post-operative CT scan

After 15 months of follow-up, the patient's condition was stable, with no radiological signs of disease progression. On a follow-up CT scan, the lung nodules have remained unchanged and no new suspicious nodules have appeared.

DISCUSSION

The diagnosis of benign leiomyoma metastasized to the lungs in a 48-year-old woman offered an unusual diagnostic and treatment puzzle, showcasing the intricate aspects of this ailment. Benign metastasizing leiomyoma (BML) is predominantly seen in women approaching menopause, with most cases being detected incidentally through imaging for other medical reasons, given that patients typically show no symptoms [10]. This observation is consistent with the results reported by Choe et al. (2017), who described a case of uterine leiomyoma with pulmonary metastases. This underscores the importance of comprehensive imaging and a multidisciplinary approach to patient management [11].

Contrary to typical clinical manifestations, the patient exhibited atypical symptoms with an unusually large uterine tumour, measuring 307 × 225 × 302 mm, which occupied the entire abdominal cavity. This size is markedly larger when compared to the smaller post-operative dimensions of tumour reported by Jo et al. (2018) following a hysterectomy and salpingo-oophorectomy [9].

Histologically, BML resembles the original benign tumour found in the uterus. Immunohistochemical testing revealed positive results for estrogen and progesterone receptors (ER/PR), smooth muscle actin (SMA), caldesmon (CALDES), CD10, desmin (DES), cyclin D1 (CYCLD1), and negative for S100 and p53, with the latter exhibiting a normal pattern of expression, low p16, and Ki67 under 2%. These findings are consistent with those described by Choe et al. (2017), suggesting BML based on the prevalence of spindle cells that tested positive for SMA, desmin, ER, and PR, but negative for S100 [11].

The identification of ER and PR markers was distinctly noted. Jautzke et al. [12] have reported on five BML instances showing ER positivity in four and PR in all of them. Padhi et al. [10] found PR and ER positivity in both lung and sternum samples in a patient, ruling out the presence of malignant sarcoma. The findings in the current case similarly demonstrate positive ER and PR immunohistochemistry in the patient.

High ER receptor expression in BML is essential for differential diagnosis. The 16 α -[18F]fluoro-17 β -oestradiol

(FES) PET/CT scan could be valuable in diagnosing BML by assessing the *in vivo* ER status of lung lesions, according to Has Simsek D. et al. Unlike malignant tumours, which typically exhibit high [18F]FDG uptake due to their increased metabolic activity, BML lesions show minimal to no [18F]FDG uptake. However, FES PET/CT demonstrates mild to intense uptake in BML lesions, confirming ER expression. This differential uptake pattern, due to the specific binding of FES to ERs highly expressed in BML, provides a more accurate diagnostic tool for distinguishing ER-positive BML lesions from malignancies. FES PET/CT, using 16 α -[18F]fluoro-17 β -oestradiol, specifically targets ERs, making it particularly effective for imaging ER-expressing tumours like BML. In contrast, [18F]FDG PET/CT, which uses fluorodeoxyglucose ([18F]FDG), highlights areas of high metabolic activity typical of malignancies. Therefore, FES PET/CT is more specific for identifying hormone-sensitive BML, whereas [18F]FDG PET/CT is better suited for detecting a broad range of cancers with high metabolic rates [13].

Research by Tong et al. (2023) underlines the metastatic nature of leiomyomas due to significant involvement in the abdominal and lung regions [14], as supported by lung biopsy histopathology. CT scans of the patient in the current case displayed several lung metastases, some up to 48 mm, a notable difference from the smaller, and defined nodules reported by Jo et al. (2018). The subsequent histological examination post-surgery definitively identified the mass as leiomyoma, removing any initial suspicions of uterine sarcoma. Thus, in diagnosing lung metastases from leiomyomas, it is critical to differentiate them from uterine sarcoma metastases. Kitayama et al. (2021) discovered distinct thickening in the lungs caused by uterine sarcoma metastases through CT imaging, showing the complexity of diagnosing such cases [15].

While BML primarily manifests with lung metastases, a review by Jautzke et al. [12] of 74 cases found lung changes to be a recurring theme. Reports also noted cases of BML affecting extrapulmonary sites, such as pelvic lymph nodes [16], deep soft tissues [17], omentum and mesentery [17], bones [10], base of the skull [18], spine [19], and even the heart [20,21].

In the presented case, satellite lesions were identified in the retroperitoneal space of the patient, which were successfully excised during surgical intervention. Importantly, these lesions were not limited to the lungs, highlighting the unusual aspects of this case. Matos et al., presented the case of a patient with lung metastases and a lytic lesion in the L4 vertebra, and a 12 cm mass in the left iliac crest, which was highlighted after intravenous contrast administration [22]. Findakly et al. presented a case of extrapulmonary metastases to the heart, with a left ventricular ejection fraction of 20%-25% and a mass measuring 4.0 cm × 3.5 cm, almost filling the entire right atrium [20].

No consensus has been reached on a standardized approach to treating BML. Options currently under consideration range from observation to excision of pulmonary lesions, removal of both ovaries, hormonal treatment, radiation of the ovaries, and systemic chemotherapy [11,21].

In the presented case, treatment included a radical hysterectomy with bilateral salpingo-oophorectomy, and resection of lesions in the retroperitoneal space. GnRH analog was used as adjuvant therapy. This treatment approach was also used in cases reported by Choe et al. (2017) and

Tong et al. (2023). Long-term GnRH analogs, which inhibit the release of the endogenous gonadotropins, have been reported to yield favourable results in numerous cases [21]. Post-operative hormone treatment should be considered if a histopathological test is positive for estrogen and progesterone receptors.

Administering a GnRH analog has demonstrated a decrease in the size of pulmonary metastatic lesions in patients, as evidenced by a subsequent CT scan in the current case. This reinforces the theory that the tumour, being positive for estrogen and progesterone receptors, is hormone-sensitive and responsive to hormone-based therapies. Typically, benign smooth muscle leiomyomas with metastases exhibit strong expression of estrogen and progesterone receptors, suggesting that hormone suppression through medication or ovary excision could lead to the diminishment or stabilization of the lesions. This implies a significant role for estrogen and progesterone in the disease's progression [23]. It has been shown that the administration of GnRH analogs does not promote tumour enlargement, as evidenced by Padhi et al. [10], who noted that in most patients the tumour mass stabilized or decreased after hormone therapy.

These insights open up a viable pathway for treating metastatic smooth muscle leiomyomas, potentially reducing the reliance on extensive surgical methods. While the majority of BML instances are detailed through case studies, the absence of prolonged follow-up makes it challenging to ascertain the lethal nature of this condition.

Data regarding BML prognosis are scant; however, it has a good prognosis. In the presented case, the patient was followed-up for a period of 15 months with no signs of tumour progression. In the studies by Matos et al. and Raposo et al., the patients were observed for six and nine months, respectively, both without disease progression [22,24]. Yeong Hun Choe et al. also report no worsening of patient's condition at the sixth-month follow-up [11]. Although BML rarely leads to death, Ofori et al. reported the death of a patient due to cancer cachexia caused by BML [25]. Usman et al. also documented the death of a patient due to cancer cachexia associated with BML [26]. Therefore, long-term follow-up of patients is recommended for early detection of possible disease progression [22].

CONCLUSION

The above BML case highlights the diagnostic and treatment complexities of this rare condition. Diagnosis relies on detailed imaging and immunohistochemical analysis, especially when atypical symptoms are present. The lack of standardized treatment underscores the need for personalized management strategies, including surgical intervention, hormonal therapy, and the use of GnRH analog for metastasis management. Further research is essential to deepen the understanding of etiology of BML, and to develop standardized treatment protocols. This presented case adds valuable insights into BML management, stressing the need for multidisciplinary care and heightened clinician awareness.

REFERENCES

1. Barnaś E, Książek M, Raś R, et al. Benign metastasizing leiomyoma: A review of current literature in respect to the time and type of previous gynecological surgery. *PLoS One*. 2017;12(4):e0175875. <https://doi.org/10.1371/journal.pone.0175875>
2. Latos W, Kawczyk-Krupka A, Strzelczyk N, et al. Benign and non-neoplastic tumours of the duodenum. *Prz Gastroenterol*. 2019;14(4):233–241. <https://doi.org/10.5114/pg.2019.90250>
3. Raś R, Książek M, Barnaś E, et al. Benign metastasizing leiomyoma in triple location: lungs, parametria and appendix. *Prz Menopauzalny*. 2016;15(2):117–121. <https://doi.org/10.5114/pm.2016.61195>
4. Karnib M, Rhea I, Elliott R, et al. Benign Metastasizing Leiomyoma in the Heart of a 45-Year-Old Woman. *Tex Heart Inst J*. 2021;48(1):e197066. <https://doi.org/10.14503/THIJ-19-7066>
5. Awonuga AO, Shavell VI, Imudia AN, et al. Pathogenesis of benign metastasizing leiomyoma: a review. *Obstet Gynecol Surv*. 2010;65(3):189–195. <https://doi.org/10.1097/ogx.0b013e3181d60f93>
6. Hann M, Manacheril R, St Pierre J, et al. Recurrent pneumothoraces in a patient with pulmonary benign metastasizing leiomyoma. *Ochsner J*. 2017;17(3):284–287.
7. Wojtyś ME, Kacalska-Janssen O, Ptaszyński K, et al. Benign Metastasizing Leiomyoma of the Lung: Diagnostic Process and Treatment Based on Three Case Reports and a Review of the Literature. *Biomedicines*. 2022;10(10):2465. <https://doi.org/10.3390/biomedicines10102465>
8. Sawai Y, Shimizu T, Yamanaka Y, et al. Benign metastasizing leiomyoma and 18-FDG-PET/CT: A case report and literature review. *Oncol Lett*. 2017;14(3):3641–3646. <https://doi.org/10.3892/ol.2017.6609>
9. Jo HC, Baek JC. Case of pulmonary benign metastasizing leiomyoma from synchronous uterine leiomyoma in a postmenopausal woman. *Gynecologic Oncology Reports*. 2018;26:33–36. <https://doi.org/10.1016/j.gore.2018.08.009>
10. Padhi P, Topalovski M. Benign Metastasizing Leiomyoma of the Uterus with Pulmonary and Bone Metastases. *Case Rep Obstet Gynecol*. 2021;2021:5536675. <https://doi.org/10.1155/2021/5536675>
11. Choe YH, Jeon SY, Lee YC, et al. Benign metastasizing leiomyoma presenting as multiple cystic pulmonary nodules: a case report. *BMC Womens Health*. 2017;17(1):81. <https://doi.org/10.1186/s12905-017-0435-6>
12. Jautzke G, Müller-Ruchholtz E, Thalmann U. Immunohistological detection of estrogen and progesterone receptors in multiple and well differentiated leiomyomatous lung tumours in women with uterine leiomyomas (so-called benign metastasizing leiomyomas). A report on 5 cases. *Pathol Res Pract*. 1996;192(3):215–23. [https://doi.org/10.1016/S0344-0338\(96\)80224-X](https://doi.org/10.1016/S0344-0338(96)80224-X)
13. Has Simsek D, Kuyumcu S, Ozkan ZG, et al. Demonstration of in vivo estrogen receptor status with 16α- [18F]fluoro-17β-oestradiol (FES) PET/CT in a rare case of benign metastasizing leiomyoma. *Eur J Nucl Med Mol Imaging*. 2021 Nov;48(12):4101–4102. doi:10.1007/s00259-021-05410-3. Epub 2021 May 25. PMID: 34031720.
14. Tong T, Fan Q, Wang Y, et al. Benign metastasizing uterine leiomyoma with lymphatic and pulmonary metastases: a case report and literature review. *BMC Womens Health*. 2023;23(1):154. <https://doi.org/10.1186/s12905-023-02237-y>
15. Kitayama T, Tanaka T, Hiraki T, et al. Pulmonary lymphatic involvement in metastatic uterine sarcomas: imaging and pathological appearance. *Radiol Case Rep*. 2021;16(9):2460–2462. <https://doi.org/10.1016/j.radcr.2021.05.076>
16. Tori M, Akamatsu H, Mizutani S, et al. Multiple benign metastasizing leiomyomas in the pelvic lymph nodes and biceps muscle: report of a case. *Surg Today*. 2008;38(5):432–435. <https://doi.org/10.1007/s00595-007-3609-2>
17. Horiuchi K, Yabe H, Mukai M, et al. Multiple smooth muscle tumours arising in deep soft tissue of lower limbs with uterine leiomyomas. *Am J Surg Pathol*. 1998;22(7):897–901. <https://doi.org/10.1097/00000478-199807000-00012>
18. Alessi G, Lemmerling M, Vereecken L, et al. Benign metastasizing leiomyoma to skull base and spine: a report of two cases. *Clin Neurol Neurosurg*. 2003;105(3):170–174. [https://doi.org/10.1016/s0303-8467\(03\)00002-7](https://doi.org/10.1016/s0303-8467(03)00002-7)
19. Zong D, He W, Li J, et al. Concurrent benign metastasizing leiomyoma in the lung and lumbar spine with elevated standardized uptake value level in positron-emission tomography computed tomography: A case report and literature review. *Medicine (Baltimore)*. 2018;97(27):e11334. <https://doi.org/10.1097/MD.00000000000011334>

20. Findakly D, Wang J. Molecular Profiling of Benign Metastasizing Leiomyoma of the Uterus Revealing Unique Novel Therapeutic Targets. *Cureus*. 2020;12(4):e7701. <https://doi:10.7759/cureus.7701>
21. Rivera JA, Christopoulos S, Small D, et al. Hormonal manipulation of benign metastasizing leiomyomas: Report of two cases and review of the literature. *J Clin Endocrinol Metab*. 2004;89(7):3183–3188. <https://doi.org/10.1210/jc.2003-032021>
22. Matos F, Santiago C, Silva D. Multisystemic Benign Metastasizing Leiomyoma: An Unusual Condition with an Atypical Clinical Presentation. *Case Reports in Radiology*. 2019;2019:1–4. <https://doi.org/10.1155/2019/7014248>
23. Fu Y, Li H, Tian B, et al. Pulmonary benign metastasizing leiomyoma: a case report and review of the literature. *World J Surg Oncol*. 2012;10:268. <https://doi:10.1186/1477-7819-10-268>
24. Raposo MI, Meireles C, Cardoso M, et al. Benign Metastasizing Leiomyoma of the Uterus: Rare Manifestation of a Frequent Pathology. *Case Reports in Obstetrics and Gynecology*. 2018;2018:1–8. <https://doi.org/10.1155/2018/5067276>
25. Ofori K, Fernandes H, Cummings M, et al. Benign metastasizing leiomyoma presenting with miliary pattern and fatal outcome: Case report with molecular analysis & review of the literature. *Respiratory Medicine Case Reports*. 2019;27:100831. <https://doi.org/10.1016/j.rmcr.2019.100831>
26. Usman M, Bakhtawar N, Rajni Sudhir R. Benign Metastasizing Leiomyoma (BML) – A Rare Phenomenon with even Rarer Radiology and Disease Course. *J Pak Soc Intern Med*. 2022;3(2):157–159