



Penetrating eye injuries – case description

Natalie Papachristoforou^{1,A-D,F}, Aleksandra Kocjan^{1,B-D}, Ismael Alsoubie^{1,B-D}, Jakub Smyk^{1,B-C}, Alicja Kamińska^{1,B-C}, Maciej Kozak^{1,2,E-F}, Ilona Pawlicka^{1,2,E-F}, Agnieszka Piskorz^{1,2,E-F}

¹ Faculty of Medicine and Health Sciences, Collegium Medicum, Andrzej Frycz Modrzewski Academy, Kraków, Poland

² Clinical Ophthalmology Department, Section 'A', Provincial Ophthalmological Hospital, Kraków, Poland

A – Research concept and design, B – Collection and/or assembly of data, C – Data analysis and interpretation, D – Writing the article, E – Critical revision of the article, F – Final approval of the article

Papachristoforou N, Kocjan A, Alsoubie I, Smyk J, Kamińska A, Kozak M, Pawlicka I, Piskorz A. Penetrating eye injuries – case description. J Pre-Clin Res. 2024; 18(3): 185–189. doi: 10.26444/jpccr/190536

Abstract

Introduction. According to 2023 statistics in the United States, penetrating eye injuries are not infrequent. Mishandling a penetrating eye injury can lead to irreversible blindness of the the patient. Therefore, proper response from doctors and prompt surgical intervention with a well-planned procedure is necessary. Two cases of penetrating eye injuries that occurred in young men are presented. Due to the implemented treatment, both patients regained full visual acuity.

Case Reports. In the first case, a 27-year-old male presented with a penetrating injury to his left eyeball. treatment involved vitrectomy, laser coagulation of the retina, and injection of gas into the vitreous chamber. In the next case, a 32-year-old male was admitted to hospital with a penetrating injury to his right eyeball and vitreous haemorrhage. An emergency posterior vitrectomy was performed with removal of the foreign body.

Conclusion. Scientific evidence proves vitrectomy to be the optimal procedure for penetrating eye injuries.

Key words

vitrectomy, penetrating eye trauma, PPV, intraocular foreign body eye injury, IOFB

INTRODUCTION

Injuries in which objects penetrate the eyeball are the second most common form of ocular trauma. It is essential to recognize that there is a broad range of penetrating eye injuries, varying from superficial penetration of the cornea to deep penetration. The majority of intraocular foreign bodies (IOFBs) do not penetrate the the Bowman's layer. Most frequently, such injuries are caused by sharp objects that perforate the upper tarsal conjunctiva, causing irritation to the cornea with each blink. The prompt removal of such objects is crucial [1,2]. If a dislodged foreign body is located in the subconjunctival space and is not causing any symptoms, it may be left untreated. A recognized classification system exists for evaluating both open and closed mechanical eye injuries. This system considers factors such as the type and severity of trauma, pupil reaction, and the affected zone [2]. It is a highly valuable tool that has demonstrated its effectiveness in providing essential information about eye injuries, and additionally functions as a prognostic marker. The Ocular Trauma Score is employed to determine the optimal treatment plan during consultations, offering crucial insights into visual acuity by considering the anatomical characteristics of the eye. It considers factors such as the degree of rupture, presence of endophthalmitis, level of perforation, retinal detachment, and afferent pupillary defect. [3]

According to the latest statistics conducted by Walsh et al. in 2023, 7.5% of people in the United States experience at least one episode of eye injury during their lifetime. From available data, it appears that only 0.6% of those who sustained injuries ultimately experienced total blindness. In 2023, approximately

2–2.5 million people suffered mechanical injuries to the eye, with 22% resulting in hospitalization and severe loss of vision [3]. In the elderly population, eye injuries are most commonly caused by falls, while among young people and adults, they can occur due to traffic accidents or at work [5]. In the youngest age group, the majority of injuries happen during sports activities [4]. Effective treatment of eye injuries relies on thorough patient examination, analysis of medical history, conducting a comprehensive eye examination, applying protective measures to reduce infections, and preventing further injury [6]. During the interview, it is crucial to gather information about the circumstances of the injury and the actions taken after the incident [7]. Characteristic symptoms of eye injuries include various changes in vision, such as decreased vision, double vision, presence of floaters or flashes, discharge in the conjunctival sac, photophobia, and sensation of a foreign body in the eye. Penetrating eye injuries often lead to permanent vision loss in affected individuals. [8]

CASE I

A 27-year-old male diagnosed with penetrating injury to the left eyeball was admitted to the emergency Ophthalmology Clinic of the Provincial Ophthalmic Hospital in Kraków, Poland. During the interview, the patient reported wearing protective glasses at the time of the incident, which involved a metal chip penetrating the eyeball. He had not received prior ophthalmic treatment and has no chronic medical conditions. Slit lamp examination, ocular biometry, and Optical Coherence Tomography (OCT) were performed. In the visual acuity test, the patient read 0.7 sc with the left eye for distance, and 0.5 sc for near vision. Tonometry readings were within the normal range (right eye=12 mmHg, left eye=12 mmHg). The anterior segment of the left eye presented mild irritation, without discharge in the conjunctival sac,

✉ Address for correspondence: Natalie Papachristoforou, Faculty of Medicine and Health Sciences, Collegium Medicum, Andrzej Frycz Modrzewski Academy, Krakow, Poland. natalienicole120@gmail.com

Received: 30.04.2024; accepted: 27.06.2024; first published: 17.07.2024

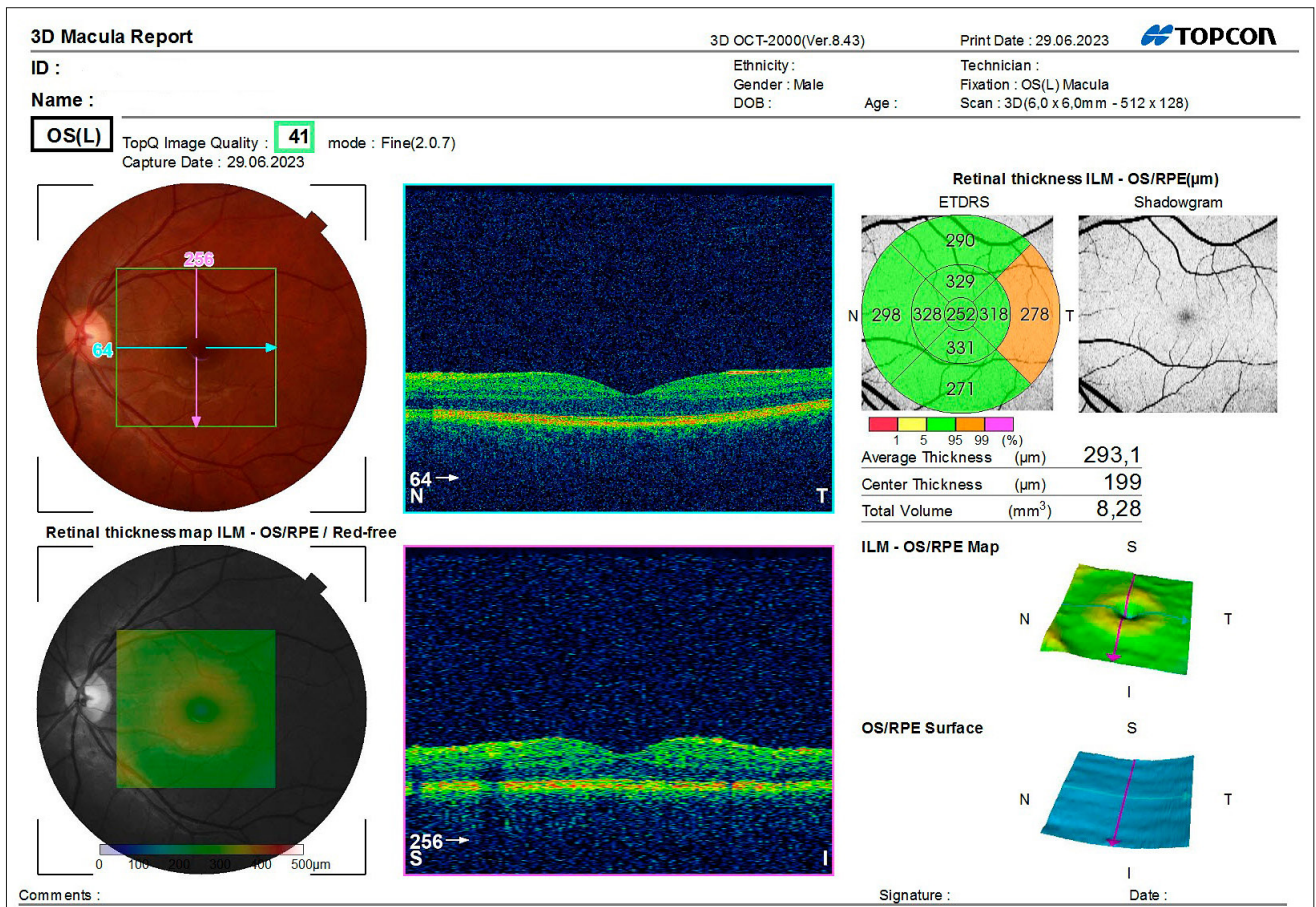


Figure 1.

with a full-thickness corneal wound located paracentrally nasally and superiorly. Seidel's test was negative, and a post-traumatic defect in the iris was noted at the site of the corneal wound.

In the examination of the fundus of the left eye, there was a partial haemorrhage into the vitreous chamber. A foreign body was embedded in the nasal part of the retina. In the ultrasound of the left eye, a haemorrhage into the vitreous chamber with a nasal-superior hyperechoic structure anterior to the retina was visible. In biomicroscopy: wound of the cornea, iris and lens, sectoral traumatic cataract and

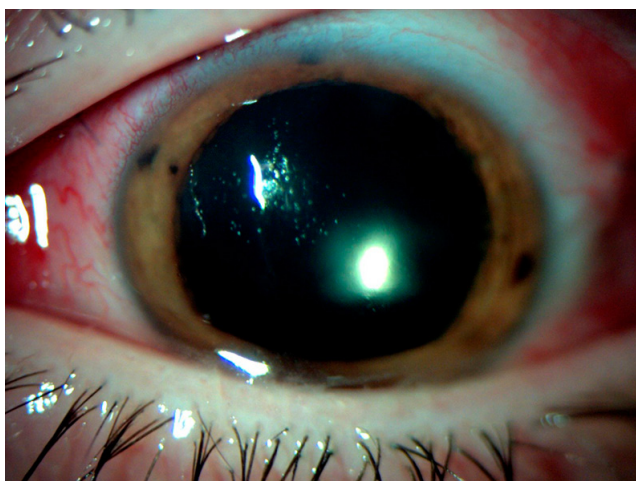


Figure 2.

haemorrhage into the vitreous chamber of the left eye were observed. The patient was qualified for emergency surgery with the administration of prophylactic cefuroxime. A vitrectomy was performed. The prescribed treatment regimen for the patient included moxifloxacin 4 times daily for 7 days, tropicamide 3 times daily for one-month post-surgery, dexapanthenol 4 times daily for 7 days, dexamethasone 4 times daily, together with bromfenac twice daily, both to be taken until the full course is completed. All the above-mentioned medications were applied to the left eye. In the post-surgical examination, the tonometry readings were 16 mmHg in the right eye and 19 mmHg in the left eye. The corneal stitches were noticeable nasally and superiorly in the anterior segment of the eye, together with newly formed cataracts. Gas in the vitreous chamber was visible in the eye fundus. During the follow-up conducted approximately one month after the injury, the patient's visual acuity in the injured eye had significantly improved. He was able to read 1.0 for distance and 0.5 for near vision. Intraocular pressure was 18 mmHg in the right eye and 23 mmHg in the left eye. Automated refractometer readings showed +0.25/-0.5/axis 144 in the right eye and +0.25/-0.75/axis 137 in the left eye.

No pathology was observed in the anterior segment of the left eye, while in the fundus, there was evidence of vascular retinal atrophy with visible pigment and localized photocoagulation areas, resulting from the procedure to remove the foreign body.

CASE II

A 32-year-old male was urgently admitted to the Ophthalmology Clinic of the Provincial Ophthalmic Hospital in Kraków for posterior vitrectomy surgery. The patient was diagnosed with a penetrating injury to the right eyeball with a foreign body and concomitant haemorrhage into the vitreous chamber. During the interview, the patient denied any previous ophthalmic treatment. He has no chronic diseases. Ocular biometry, slit lamp examinations, and OCT were performed. In the anterior segment of the right eye, a penetrating eye injury was visible. Tonometry readings were 12 mmHg for the right eye and 11 mmHg for the left eye. On admission, visual acuity for distance was 0.9 sc in the right eye and 0.7 sc in the left eye. Near vision was 0.5 binocularly. The patient was qualified for immediate surgery, where posterior vitrectomy, irrigation, and cleansing were performed. The corneal wound was sutured, and cefuroxime was administered into the anterior chamber of the eye. The following treatments were administered to the right eye: moxifloxacin 4 times daily taken for 4 days, dexamethasone 4 times daily, together with bromfenac administered twice daily, taken until the full course of medication was completed, tropicamide 3 times daily for one-month post-surgery, dexamethasone 4 times daily for 7 days, and tobramycin 4 times daily for 4 days. A postoperative visual acuity test revealed a significant decrease in visual acuity in the right eye, in which the patient only perceived hand movements for distance vision, and no reading was possible for near vision.

Intraocular pressure was 18 mmHg in the right eye and 17 mmHg in the left eye. During slit lamp eye examination, a slight irritation was observed in the eyeball, with sutures on the sclerotomy sites. Subconjunctival haemorrhage was noted temporally, extending peripherally from the nasal area, with a transilluminating iris wound and sectoral cataract (nasally-inferiorly). Gas was visible in the vitreous chamber. Treatment with metronidazole, moxifloxacin, telmisartan, tetanus toxoid, paracetamol, and steroids was initiated. Regular ophthalmic check-ups were recommended, together with wearing protective glasses and ENT examination.

After the surgery, a tomography of the orbital cavity was advised to check for the presence of other foreign bodies within the socket. The examination showed no shadows of foreign bodies in the scanned area. During the follow-up examination conducted 6 months after the incident, the patient’s visual acuity showed significant improvement. For distance vision, the patient could read 1.0 in both eyes, respectively. For near vision, the patient could read 0.5 binocularly. In the anterior segment of the right eye, a sectoral cataract and a scar within the lens were noticeable. No pathological changes were observed in the fundus examination of the right eye. Tonometry readings indicated intraocular pressure of 18 mmHg in the right eye and 19 mmHg in the left eye. In autorefractive testing, the readings for the right eye were +0.25 -0.75 axis 118, and for the left eye were -0.25 - 0.75 axis 95.

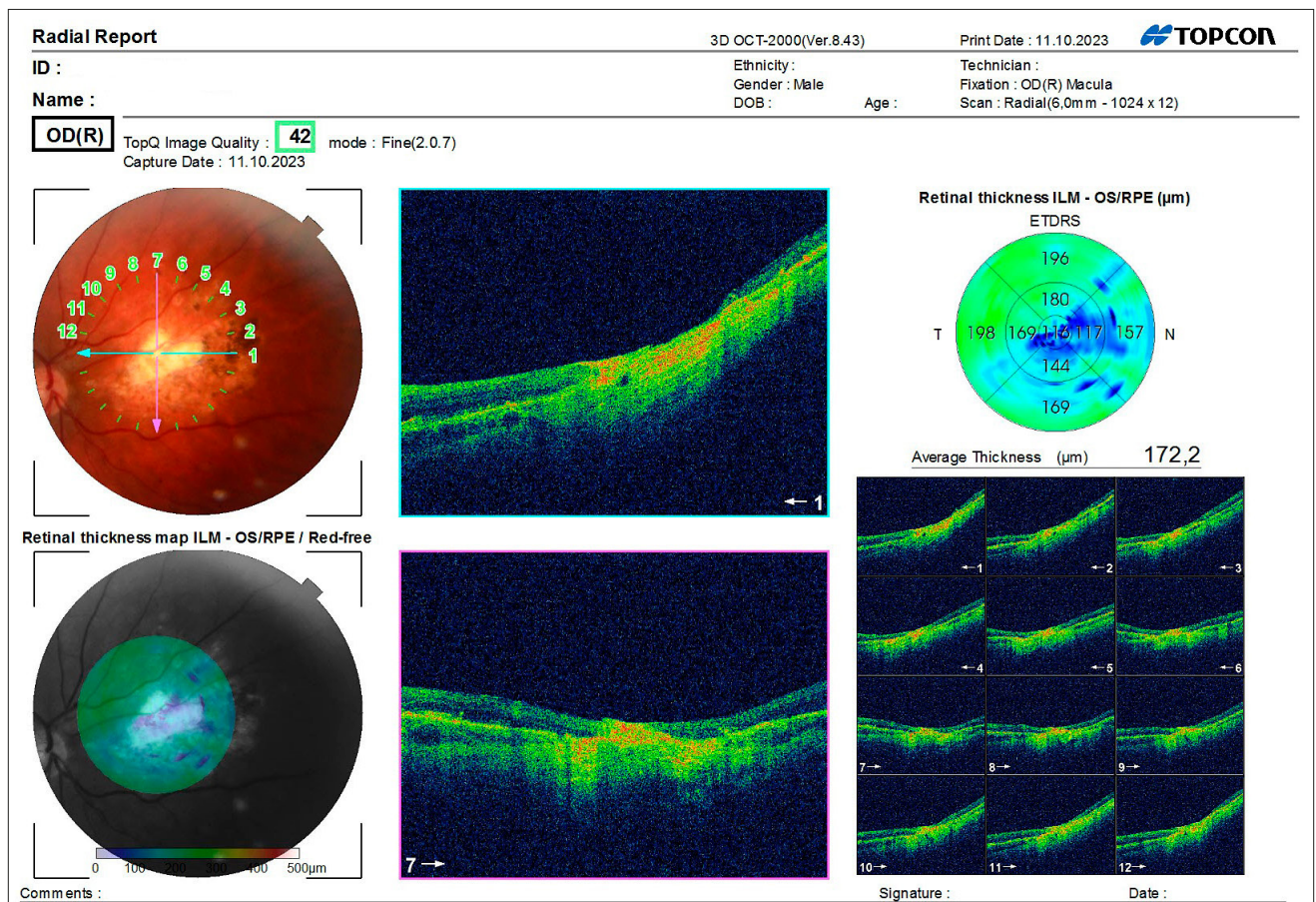


Figure 3.

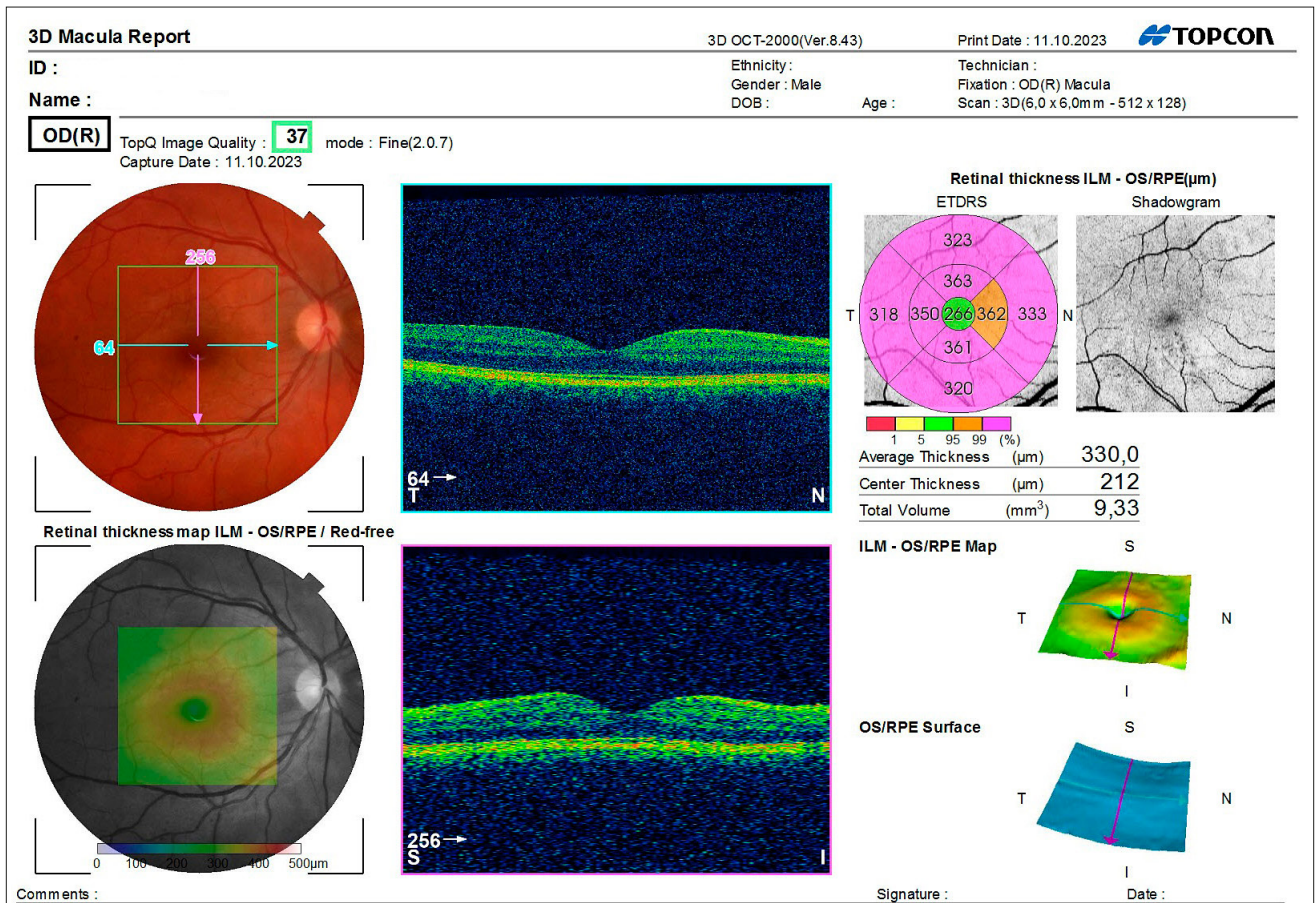


Figure 4.

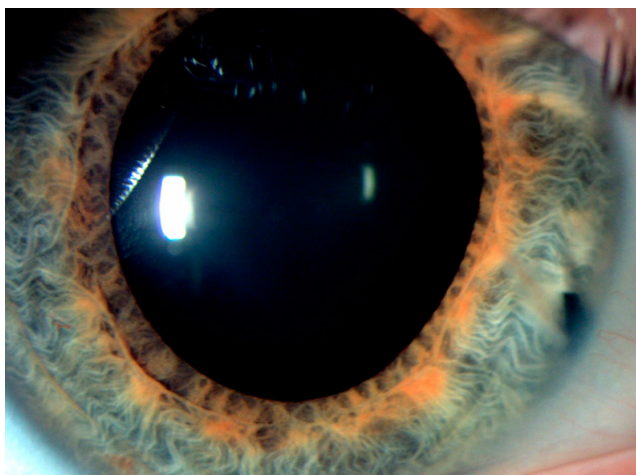


Figure 5.

DISCUSSION

For the classification of ocular injuries, the worldwide Birmingham Eye Trauma Terminology (BETT) classification is used, which standardizes the medical terminology and facilitates the description of injuries [2]. In the case of blunt traumas, it is important to conduct a comprehensive ophthalmic examination and perform ultrasonography (USG), together with ultrabiomicroscopy (UBM) of the eyeball to exclude possible retinal detachment, lens damage,

or angle reduction. X-ray imaging (X-ray) and computed tomography (CT) are used to diagnose accompanying craniofacial injuries.

Corneal injuries represent a frequent form of eye trauma. Typically, corneal epithelial erosion is short-lived due to the cornea’s strong regenerative ability. Blunt traumas often result in rupture of the anterior or posterior lens capsule, leading to the formation of traumatic cataracts.

Depending on the location of the foreign body in the cornea (anteriorly or posteriorly to the muscle insertion), there are 2 therapeutic pathways. If the foreign body is located in the anterior part of the eye without symptoms, it can be removed using surgical instruments. However, if the foreign body is distal to the muscle insertion, *pars plana* vitrectomy (PPV) is recommended [2]. In each case, it is imperative to thoroughly assess whether the benefits of surgically removing the foreign body from the eyeball outweigh the potential risks associated with leaving the patient with the foreign body inside the eye.

Prior to the emergence of vitrectomy, surgical reconstruction of the eyeball was unattainable in the medical field. However, with the advancements in modern medicine and the introduction of vitreoretinal surgery, there has been a notable shift in the management of patients with eye trauma.

According to F. Kuhn et al. (2020), early vitrectomy is typically conducted within a few days following trauma, while the classic (delayed) procedure takes place after a period of 10–14 days [9]. In cases where there is a high risk of post-retinal incarceration into the scleral wound, prophylactic

chorioretinectomy is recommended. Although prophylactic chorioretinectomy is highly effective, it may not be suitable for all types of trauma, and there is a risk of proliferative vitreoretinopathy (PVR) development in untreated areas [9]. A research study conducted by D. Jackson et al. (1982) in the late 90s has demonstrated that vitrectomy performed within 72 hours post-trauma yields the best prognosis for visual recovery and intact visual acuity, whereas even a delay of just 3 days results in significantly poorer outcomes. [10] The concept of early vitrectomy, as affirmed by Kuhn F et al. (2020), asserts that conducting vitrectomy shortly after a traumatic injury results in optimal outcomes and reduces postoperative complications. [9] Delayed surgery can lead to scar formation which may result in corneal opacity, glaucoma, or retinal detachment due to PVR. These observations are also applicable to the aforementioned patients. Based on the described cases and therapeutic outcomes of penetrating ocular injuries, it can be concluded that vitrectomy is an integral component of proper therapeutic management.

CONCLUSION

Immediate identification of eye perforating trauma is a priority in ensuring effective medical care. An accurate and swift diagnosis is crucial, not only for trauma treatment but

also to aid ophthalmologists in their actions. Early vitrectomy reduces the risk and number of patients exposed to total vision loss and its complications. According to scientific research and the aforementioned clinical cases, it can be confidently stated that vitrectomy is the most beneficial procedure for individuals who have suffered penetrating eye globe injuries.

REFERENCES

1. Koberda M, et al. Numerical and Clinical Analysis of an Eyeball Injuries under Direct Impact. *IJOMEH*. 2023;36(2):263–273. <https://doi.org/10.13075/ijomeh.1896.01913>
2. Kuhn F. *Ocular Traumatology*. New York; 2008.
3. Walsh A, Lewis K. *EMS Management of Eye Injuries*. <https://www.ncbi.nlm.nih.gov/books/NBK585131/> (access: 2024.04.10).
4. Heath Jeffery RC, Dobes J, Chen FK. Eye injuries: Understanding ocular trauma. *AJGP*. 2022;51(7):476–482. doi:10.31128/AJGP-03-21-5921
5. Pogrzebielski A. *Interna Szczeklika*. <https://www.mp.pl/pacjent/okulistyka/zdroweoczy/68655,budowa-narzadu-wzroku> (access: 2024.04.10).
6. Feng, Kang, et al. Prognostic Factors and Long-Term Outcomes of Eye-Globe Perforation: Eye Injury Vitrectomy Study. *ELSEVIER*. 2021;52(2):286–291. <https://doi.org/10.1016/j.injury.2020.09.064>
7. Kuhn F, Morris R. Early vitrectomy for severe eye injuries. *EYE*. 2021;35:1288–1289. <https://doi.org/10.1038/s41433-020-01308-w>
8. Coleman J. Early Vitrectomy in the Management of the Severely Traumatized Eye. *AJO*. 1982;93(5):543–551. [https://doi.org/10.1016/s0002-9394\(14\)77367-2](https://doi.org/10.1016/s0002-9394(14)77367-2)