



# Phoniatic evaluation, diagnosis and treatment of voice disorders in the laryngeal nerves paralysis

Krzysztof Jurkiewicz<sup>1,A-D</sup> , Daria Markowska<sup>1,A-D</sup> 

<sup>1</sup> Student Research Group, Department of Otolaryngology, Medical University, Wrocław, Poland

A – Research concept and design, B – Collection and/or assembly of data, C – Data analysis and interpretation, D – Writing the article, E – Critical revision of the article, F – Final approval of the article

Jurkiewicz K, Markowska D. Phoniatic evaluation, diagnosis and treatment of voice disorders in the laryngeal nerves paralysis. *J Pre-Clin Clin Res.* 2022; 16(3): 114–117. doi: 10.26444/jpccr/152939

## Abstract

**Objective.** The aim of the study was to specify and collect important information on the anatomy of the laryngeal nerves and the types of paralysis, as well as paresis and fixation, which is not due to dysfunction of the recurrent laryngeal nerve, but is caused by immobility of the vocal fold as a result of a mechanical obstruction. We focused on the analysis of this condition in terms of clinical symptoms contributing to phoniatic disorders, including dysphonia in the majority of patients with palsy of the laryngeal nerves, as well as the occurrence of dysphagia in slightly more than 30% of people suffering from paralysis. Changes in the patient's quality of life are significant enough to develop the subject in terms of presenting the possibilities of diagnosis, and to present the types of treatment of phoniatic dysfunctions, because an increasing number of patients decide to undergo surgical rehabilitation, including such surgical procedures as thyroplasty, aimed at improving the quality of life of patients.

**Review Methods.** The focus was on finding the most up-to-date information from the world of science, both on the Internet and in printed literature. Searching Internet resources was carried out with the use of medical publication databases Embase and UpToDate. In addition, part of the bibliography was found on PubMed and PubMed Central. The exploration process was based on key words. A review of the literature was carried out using the basic terms: retrograde laryngeal nerve, in combination with the following entries: paralysis, aphonia, diagnosis, treatment. All the publications selected, with one exception about acute bilateral recurrent palsy of the laryngeal nerve, published in 1988, were published in the 21st century. Special emphasis was placed on presenting the most up-to-date knowledge possible, therefore the vast majority of the literature was published after 2014. Several items published in the current calendar year can be found in the bibliography. Clinical trials were also taken into account, paying particular attention to the number of patients tested, the selection of the research group, research methods and analysis of the results. Many of the online sources found did not meet the selected criteria, most often because the subject was incomplete or the results were reported from too small a group of patients. The criteria adopted while browsing the printed literature were primarily the year of publication and the thematic scope of the issues described.

## Key words

recurrent laryngeal nerve, paralysis, aphonia, diagnosis, treatment

## INTRODUCTION

Given the intricate pathway of the laryngeal nerves, there are many injuries that can cause pathology, as well as damage to the nerve anywhere in its path that can paralyze it and impair voice function. Nerves can conduct sensory or motor stimuli. Often, as is the case with the recurrent laryngeal nerve, it happens that one fibre transmits both types of stimuli. The nerve in question has a very characteristic course and, taking this into account, there are many possibilities of damage, causing a far-reaching dysfunction of the organism. Due to advances in modern medicine, a variety of diagnostic methods have emerged, as well as the possibility of assessing and classifying palsy of the laryngeal nerves, as well as phoniatic diagnostics, thanks to which specific ailments and voice changes can be assigned to a specific type of paralysis. Multidirectional classification and specialized diagnostics

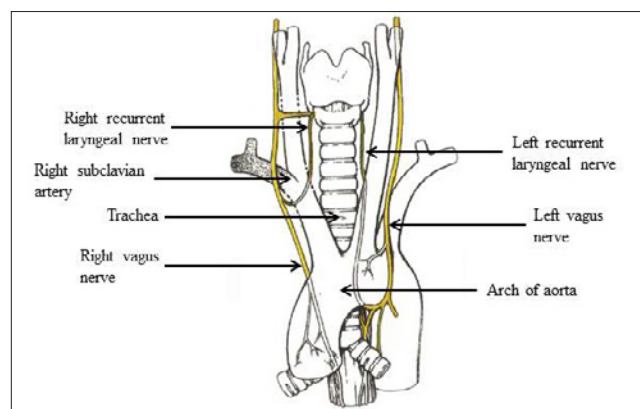
make it possible to decide on the possibility and method of treating palsy of the laryngeal nerves.

**Anatomy.** The retrograde laryngeal nerve (nervus laryngeus recurrens) is an even branch departing from the vagus nerve at the border of its cervical and thoracic parts. The left nerve wraps around the aortic arch, while the right nerve wraps around the right subclavian artery. Both branches run ascendingly in the furrow between the trachea and esophagus and cross the inferior disc artery at this point. This is a site at particular risk of damage due to the thyroid gland procedures. The nerve in question reaches the larynx as the inferior laryngeal nerve, which sensitively supplies the laryngeal mucosa below the glottis, and locally supplies all the muscles of the larynx, with the exception of the cricothyroid muscle [1]. Thus, paralysis of this structure will result in aphonia, or phonation difficulties, together with hoarseness in unilateral paralysis, as well as the appearance of dyspnea due to the narrowing of the glottis and the presence of auscultated stridor [2]. It is worth mentioning here the optional routes of the described nerve. About 0.7% of the

✉ Address for correspondence: Krzysztof Jurkiewicz, Student Research Group, Department of Otolaryngology, Medical University, Wrocław, Poland  
E-mail: jurkiewicz1997@wp.pl

Received: 09.08.2022; accepted: 23.08.2022; first published: 02.09.2022

world's population has a right non-recurrent laryngeal nerve, while the left non-recurrent laryngeal nerve is extremely rare. The alternative course in these patients is associated with the lack of nerve passage under large vessels – the right one does not scroll under the right subclavian artery, while the left one does not scroll under the aortic arch. Such an anomaly is due to a developmental defect in this nerve, but its existence without associated vascular anomalies has no clear embryological explanation. In 89.3% of cases, the presence of the non-recurrent right recurrent laryngeal nerve is correlated with a congenital defect of the right subclavian artery. The described pathology is closely associated with a much greater risk of damage to this structure during thyroid surgery and parathyroid glands [3, 4, 5]



**Figure 1.** Type I with origin of the non-recurrent main trunk above the level of the inferior thyroid artery (not shown) and a thin-calibre, recurrent branch [6]

**Types of shock.** Paralysis of the nerve in question causes a neurogenic disturbance of the function of the vocal folds. The literature distinguishes several pathologies of the mobility of these structures. The first is paralysis, i.e. complete disruption of continuity, resulting in the lack of conduction of neuronal impulses and, consequently, permanent, irreversible immobilization of the folds. Another pathology is paresis, i.e. partial interruption of the nerve impulse, manifested by weak or abnormal movement of the laryngeal muscles [7]. It is additionally worth mentioning here about fixation, which does not result from dysfunction of the recurrent laryngeal nerve, but presents a similar clinical picture. The vocal fold is immobile due to a mechanical obstruction to its movement, such as cricoid arthritis, a joint or scarring of the posterior commissure [8]. The symptoms that accompany it include hoarseness, cough and exertional dyspnea resulting from the narrowing of the glottis – partial or complete. Depending on the degree of constriction, the symptoms will be more severe, which is obviously associated with a direct threat to the patient's life [9].

**Phoniatic evaluation.** Diagnostic methods for the assessment of voice function (phoniatic assessment) that are recommended, apart from the interview and physical examination, include the performance of a listening assessment of the voice, video laryngostroboscopic examination (VLS), acoustic tests and self-assessment of voice quality [10]. Any damage to the recurrent laryngeal nerve requires precise laryngological and phoniatic diagnostics as well as voice rehabilitation, which is often supported pharmacologically [11].

Damage to the CTM muscle and the outer branch of the superior laryngeal nerve (EBSLN) leads to a reduction in the Fundamental Frequency (F0) and voice, and reduces the patient's ability to produce a high-frequency voice. This kind of dysphonia is especially audible in high voices (soprano), while in people who do not use their voice professionally, it may be imperceptible. Among the complaints reported by patients, there may be vocal fatigue and phonation effort, the voice becomes breathless [12].

A retrospective study in a cohort of 325 patients with unilateral palsy of the laryngeal nerve, showed that 98.7% suffered from dysphonia and 38.7% had dysphagia, while exercise-induced dyspnea was present only in 0.9% [13]. Superior laryngeal nerve palsy (SLNp) can lead to a significant narrowing of the pitch range, asymmetry of the vibrational phases of the vocal folds, and acoustic aperiodicity, thus leading to an overall poor voice quality [14].

## DIAGNOSTICS

There are many ways to diagnose vocal fold paralysis. The basis is, of course, a thorough interview and physical examination. The history of the disease reveals important clues about the causes that may determine the diagnostic procedure. Voice diagnostics serves to evaluate its quality and performance. On the other hand, the phoniatic evaluation of the voice is necessary for planning and assessing the success of possible speech therapy [15, 16].

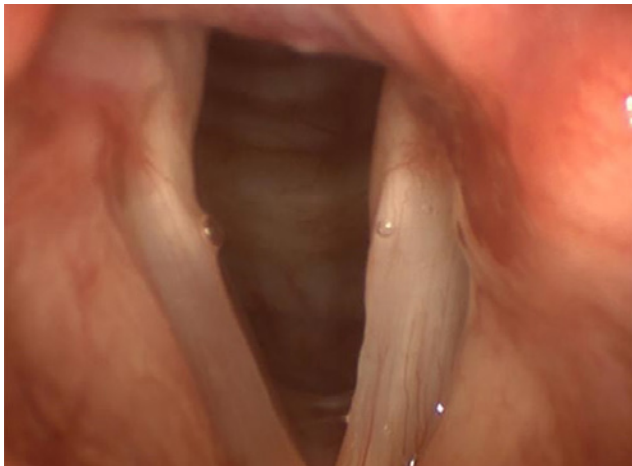The accepted standards for operative damage to the recurrent laryngeal nerve are to wait 6 – 12 months in the hope that the function of the nerve, and thus the vocal fold, will return, regardless of the cause: ligation, partial cut, contusion, strain, or thermal damage to the nerve during coagulation. If the nerve is cut completely, function cannot be restored [11].

In patients with vocal fold paralysis, direct laryngoscopy is usually considered prior to computed tomography, which has excellent reliability in assessing the movement of the vocal folds and is now considered the gold standard in the diagnosis of this disorder. Stroboscopy is an additional tool that can be used to assess vibrations of the vocal folds [17, 18].

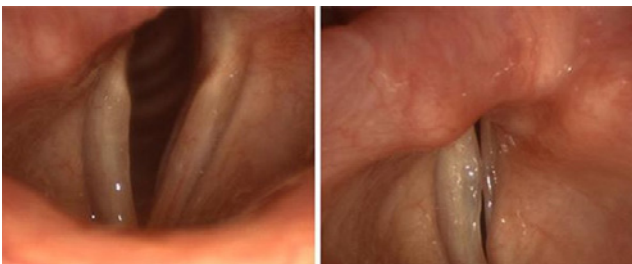The photos below show frames from the stroboscopic examination. Figure 2 shows paralysis of the right recurrent laryngeal nerve with the functionality of the left nerve preserved. The frame was taken while the patient breathes freely. The pathology occurred as a result of radical surgery on the right lung. A significant narrowing of the gap is visible on the side of the infestation (right side). The patient has moderate difficulty breathing and a characteristic wheezing sound with free air exchange.

Figure 3 shows a dysfunction analogous to that presented above, except that it is the left retrograde laryngeal nerve that is completely paralyzed. The photo on the left was taken while breathing calmly, while the right photo was taken with the most severe attempt to shorten the vocal folds. The places of regurgitation and incomplete closure of folds as a result of the paralysis of the retrograde laryngeal nerve are depicted. An external symptom of this dysfunction is disturbances in correct phonation.

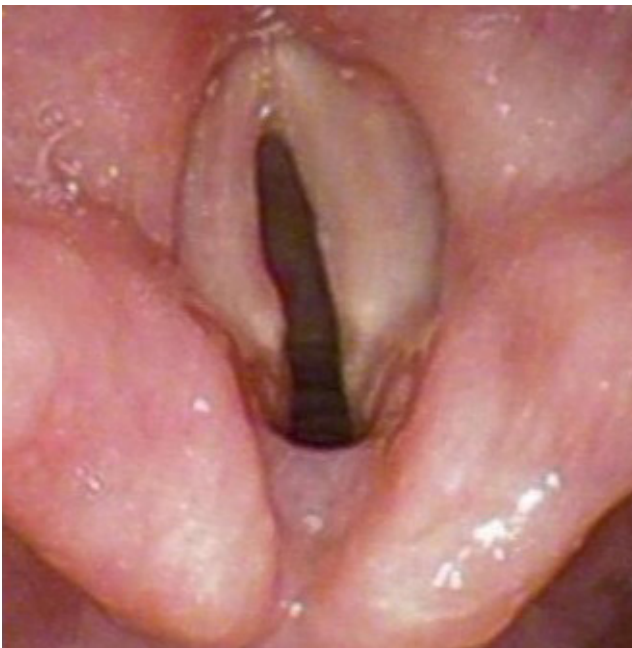The situation presented in Figure 4 is definitely a more serious problem. Bilateral paralysis of the vocal folds is shown. The photo was taken while breathing freely, with the vocal folds in the fully open position. There is a pathological



**Figure 2.** Paralysis of the right recurrent laryngeal nerve [19]



**Figure 3.** Paralysis of the left recurrent laryngeal nerve (calm breathing and shortened vocal folds)[19]

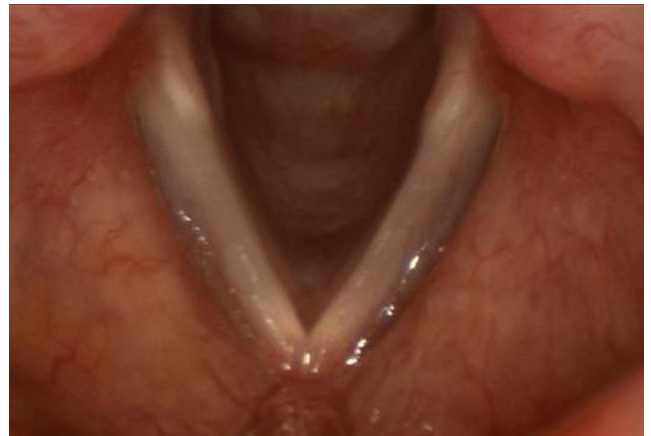

**Figure 4.** Bilateral paralysis of the vocal folds [20]

narrowing of the airways of this patient by about 75%. The patient suffers from severe dyspnoea at rest.

For comparison, below (Fig. 5) there is a correct stroboscopic photo showing the complete opening of the vocal folds in vocal rest, and showing the physiological width of the gap that determines the flow of the correct air volume.

A decisive advantage of computed tomography is the ability to visualize the entire length of the retrograde laryngeal nerves, as well as detect signs of possible paralysis of the



**Figure 5.** Healthy vocal folds – calm breathing [21]

vocal cords [22]. In some cases, a chest X-ray is ordered and performed in order to exclude a possible pulmonary cause, e.g. tumour compression on a nerve. Laryngeal ultrasound is also used, and is particularly often considered in the assessment of recurrent damage to the laryngeal nerve. One study assessed 112 patients with vocal cord paralysis by ultrasound and compared it with laryngoscopy. Laryngeal ultrasound showed 83.3% sensitivity and 97.2% specificity in detecting vocal cord paralysis, and had a negative predictive value of 99% [23].

The fact that nearly half of the patients with unilateral RLN or SLN paralysis before surgery may be asymptomatic, prompted surgeons to include laryngoscopy or videostroboscopy for preoperative evaluation. In terms of self-assessment of dysphonia, many quality-of-life (QoL) tools have been developed and used [24].

Auditory-perceptual assessment enables doctors to monitor changes in voice quality over time. There are two scales that can be used to measure voice quality subjectively. The first is GRBAS (G – grade – general severity, R – roughness – roughness, B – breathiness – breathing, A – asthenia – weakness, S – strain – tension). Each aspect is scored from 0 – 3 points [25]. The second scale is CAPE-V (Consensus Auditory Perceptual Evaluation of Voice), used in a similar way, scoring from 0 – 100 points [26].

Breathing tests such as spirometry and body plethysmography are also performed. Their purpose is to measure impaired laryngeal respiratory flow, especially in patients with bilateral paralysis [27].

Another type of research, although available in only a few research centres, is Laryngeal Muscle Electromyography, which measures the electrical activity of the laryngeal muscles using thin needle electrodes. This method distinguishes nerve damage from other causes of impaired mobility of the vocal fold. Laryngeal EMG can predict the development of recurrent paralysis of the laryngeal nerve with some probability [28].

In the differential diagnosis of recurrent damage to the laryngeal nerve with resulting paralysis of the vocal cords, the following factors should be taken into account in order to exclude them before an unequivocal diagnosis is made: iatrogenic effects, malignant neoplasms, trauma (including the neck and chest, except the larynx), neurology – including stroke (especially lateral medullary syndrome) and idiopathic factor [29].

**Treatment.** In a study of a group of patients with unilateral palsy of the laryngeal nerve, surgical rehabilitation was

performed in 44% of the patients (in 55 patients thyroplasty under local anesthesia, and in 88 patients – intracardiac injection under general anesthesia). Analysis of the evolution of treatment methods showed a growing number of patients undergoing surgical rehabilitation, an increasing number of patients undergoing surgery under local anesthesia (thyroplasty) and refusing any surgical rehabilitation [13]. However, the effectiveness of speech therapy depends on the severity of symptoms associated with unilateral palsy of the laryngeal nerve [30].

If injuries are less severe, they are monitored for six months or, if necessary, conservative treatment. In the case of ineffectiveness, techniques for medialization of the vocal folds should be considered, which include procedures such as mediation thyroplasty, injection laryngoplasty, tincture adduction and laryngeal reinnervation. Injuries require an individual approach to the patient as they can vary significantly depending on various factors, including the mechanism of the injury and extent of the injury [29].

According to the current guidelines presented at the World Voice Congress in Istanbul (3rd World Voice Congress, Istanbul, 2006) and the European Voice Conference (7th Pan European Voice Conference, Groningen, 2007) regarding the treatment of voice disorders, the case of rehabilitation of the voice of a patient with laryngeal nerve palsy is based on voice emission correction, based on the close cooperation of an ENT doctor / phoniatriest with a speech-language pathologist trained in the field of voice emission techniques [31].

## CONCLUSIONS

Although paralysis resolves spontaneously in a small group of patients, the majority of patients still struggle with disorders related to voice quality disorders. Due to the complexity of the laryngeal nerves, there are several equal types of paralysis. However, there is a growing awareness of the problem posed by paralysis of the laryngeal nerves, including phoniatic disorders as well as problems that hinder normal functioning, e.g., swallowing disorders.

Multidirectional diagnostics, with the use of various imaging methods, as well as modern methods of treatment, guarantee restoration of full or partial comfort of life. People struggling with this problem have several treatments at their disposal. The non-invasive ones include steroid pharmacotherapy and voice rehabilitation. On the other hand, nowadays, with relatively easy access to professional therapy, more and more often patients decide to undergo surgical treatment of the effects of unilateral palsy of the retrograde laryngeal nerve. The surgical procedure is the endoscopic removal of one of the vocal folds or its ligature. The purpose of this procedure is to keep the airway open by physically widening the glottis.

## REFERENCES

- Gworys B. Kompendium z anatomii prawidłowej człowieka. Wrocław: Medpharm Polska; 2019. II: p. 114.
- Wiechno W. Tyreoidektomia – jak chronić nerw wsteczny. *Chirurgia po Dyplomie*. 2018; 4.
- Marchesi M, Biffoni M, Faloci C, Nobili Benedetti R, Notari P, Mariotti F, Cresti R. Il nervo laringeo inferiore non ricorrente: descrizione di 7 casi osservati dal 1987 [The inferior nonrecurrent laryngeal nerve: a report of 7 cases observed since 1987]. *G Chir*. 2000 Jan-Feb;21(1-2):25–8. Italian. PMID: 10732377.
- Yetiştir F, Özkardeş AB, Dündar HZ, Birkan B, Çiftçi AB, Kılıç M. Non-recurrent laryngeal nerve. *Ulus Cerrahi Derg*. 2013 May 28;30(2):112–4. doi: 10.5152/UCD.2013.22. PMID: 25931895; PMCID: PMC4379830.
- Henry BM, Sanna S, Graves MJ, Vikse J, Sanna B, Tomaszewska IM, Tubbs RS, Walocha JA, Tomaszewski KA. The Non-Recurrent Laryngeal Nerve: a meta-analysis and clinical considerations. *PeerJ*. 2017 Mar 21;5:e3012. doi: 10.7717/peerj.3012. PMID: 28344898; PMCID: PMC5363258.
- Weiland G, Mangold G. Verlaufsvarietäten des Nervus laryngeus inferior; Chirurgische Anatomie, Klassifikation, Diagnostik. *Springer Medizin*. 2004; 2.
- Rosenthal LH, Benninger MS, Deeb RH. Vocal fold immobility: a longitudinal analysis of etiology over 20 years. *Laryngoscope*. 2007; 117(10): 1864–70.
- Gelbard A, Francis DO, Sandulache VC, Simmons JC, Donovan DT, Ongkasuwan J. Causes and consequences of adult laryngotracheal stenosis. *Laryngoscope*. 2015; 125: 1137–1143.
- Laubert A. Acute bilateral recurrent laryngeal nerve paralysis, a symptom of Shy-Drager syndrome. *HNO*. 1988; 36(7): 290–2.
- Ólszewski J, Nowosielska-Grygiel J. Nowe metody diagnostyczne oceny czynności głosu dla potrzeb foniatry i logopedy. *Logopaedica Lodziensis*. 2017; 1: 91–99.
- Misiólek M, Stelmańska K, Twardokey M, Sowa P, Lisowska G. Operacyjne uszkodzenia nerwów krtaniowych. *Pol Przegl Otorinolaryngol*. 2014; 3: 15–19.
- Berger G, Kosztyła-Hojna B, Chyczewski L. Wpływ anatomicznych uwarunkowań nerwów krtaniowych na wyniki neuromonitoringu śródoperacyjnego w zabiegach tyroidektomii oraz na wyniki funkcjonalne po laryngektomiach oszczędzających. *Pol J Surg*. 2019; 91(2): 30–37.
- Laccourreye O, Papon JF, Kania R, Ménard M, Brasnu D, Hans S. Unilateral laryngeal paralyses: epidemiological data and therapeutic progress. *Presse Med*. 2003; 32(17): 781–6.
- Orestes MI, Chhetri DK. Superior laryngeal nerve injury: effects, clinical findings, prognosis, and management options. *Curr Opin Otolaryngol Head Neck Surg*. 2014; 22(6): 439–43.
- Corrado B, Ciardi G, Bargigli C. Rehabilitation Management of the Charcot-Marie-Tooth Syndrome: A Systematic Review of the Literature. *Medicine*. 2016; 95(17): e3278.
- Misono S, Merati AL. Evidence-based practice: evaluation and management of unilateral vocal fold paralysis. *Otolaryngol Clin North Am*. 2012; 45(5): 1083–108.
- Dankbaar JW, Pameijer FA. Vocal cord paralysis: anatomy, imaging and pathology. *Insights Imaging*. 2014; 5(6): 743–51.
- Madden LL, Rosen CA. Evaluation of Vocal Fold Motion Abnormalities: Are We All Seeing the Same Thing? *J Voice*. 2017; 31(1): 72–77.
- Sean Parker Institute for the Voice. Weill Cornell Medical College site <https://voice.weill.cornell.edu/voice-disorders/paralysis-unilateral> [access: 21.08.2022]
- UCI Health Voice & Swallowing Center site <https://throatdisorder.com/breathing-disorders/bilateral-vocal-fold-paralysis/> [access: 21.08.2022]
- Sean Parker Institute for the Voice <https://voice.weill.cornell.edu/voice-evaluation/normal-voice-function> [access: 21.08.2022]
- Sean Parker Institute for the Voice <https://voice.weill.cornell.edu/voice-evaluation/normal-voice-function> [access: 21.08.2022]
- Estes C, Sadoughi B, Mauer E, Christos P, Sulica L. Laryngoscopic and stroboscopic signs in the diagnosis of vocal fold paresis. *Laryngoscope*. 2017; 127(9): 2100–2105.
- Rybakova A, Bausys A, Matulevicius A, et al. Recurrent laryngeal nerve injury assessment by intraoperative laryngeal ultrasonography: a prospective diagnostic test accuracy study. *Videosurgery and Other Miniinvasive Techniques*. 2019; 14(1): 38–45.
- Papadakis CE, Asimakopoulou P, Proimos E, Perogamvrakis G, Papoutsaki E, Chimona T. Subjective and Objective Voice Assessments After Recurrent Laryngeal Nerve-Preserved Total Thyroidectomy. *J Voice*. 2017; 31(4): 515.e15–515.e21.
- León Gómez NM, Delgado Hernández J, Luis Hernández J, Artazkoz del Toro JJ. Objective Analysis Of Voice Quality In Patients With Thyroid Pathology. *Clin Otolaryngol*. 2022; 47: 81–87.
- Zraick RL, Kempster GB, Connor NP, et al. Establishing validity of the Consensus Auditory-Perceptual Evaluation of Voice (CAPE-V). *Am J Speech Lang Pathol*. 2011; 20(1): 14–22.
- Jiang Y, Gao B, Zhang X, Zhao J, Chen J, Zhang S, Luo D. Prevention and treatment of recurrent laryngeal nerve injury in thyroid surgery. *Int J Clin Exp Med*. 2014; 7(1): 101–7.
- Kneisz L, Volk GF, Mayr W, Leonhard M, Pototschnig C, Schneider-Stickler B. Objectivation of laryngeal electromyography (LEMG) data: turn number vs. qualitative analysis. *Eur Arch Otorhinolaryngol*. 2020; 277(5): 1409–1415.
- Culp JM, Patel G. Recurrent Laryngeal Nerve Injury. *NLoM Online* <https://www.ncbi.nlm.nih.gov/b...> (access: 2022.05.23).
- Laccourreye O, Malinvaud D, Ménard M, Bonfils P. Unilateral laryngeal nerve paralysis in the adult: Epidemiology, symptoms, physiopathology and treatment. *Presse Med*. 2014; 43(4 Pt 1): 348–52.
- Woźnicka E, Niebudek-Bogusz E, Śliwińska-Kowalska M. Ocena efektów terapii głosu w dysfonii porażeniowej – studium przypadku. *Otorinolaryngol*. 2011; 10(3): 138–145.