



# Periodontal and orthodontic treatment of a patient with advanced periodontitis – Case Report and 3-year follow-up

Mirella Stańdo-Retecka<sup>1,A-D</sup>, Agnieszka Szlendak<sup>2,B-C</sup>, Natalia Lewkowicz<sup>1,D-F</sup>

<sup>1</sup> Medical University, Lodz, Poland

<sup>2</sup> Private dental office euroDent, Piotrkow Trybunalski, Poland

A – Research concept and design, B – Collection and/or assembly of data, C – Data analysis and interpretation, D – Writing the article, E – Critical revision of the article, F – Final approval of the article

Stańdo-Retecka M, Szlendak A, Lewkowicz N. Periodontal and orthodontic treatment of a patient with advanced periodontitis – Case Report and 3-year follow-up. J Pre-Clin Clin Res. 2022; 16(3): 69–74. doi: 10.26444/jpccr/152724

## Abstract

**Introduction.** Periodontitis is a chronic multifactorial disease induced by a microbial biofilm leading to progressive destruction of the tooth-supporting tissue. Severe periodontitis often contributes to pathologic tooth migration (PTM) or tooth loss. In consequence, patients with advanced periodontitis can require, apart from periodontal therapy, orthodontic and/or prosthetic treatment.

**Case Report.** A multidisciplinary approach is presented to the treatment of stage IV periodontitis in a 46-year-old woman. Non-surgical periodontal therapy followed by orthodontic treatment were performed. A 3-year follow-up demonstrated complete resolution of periodontal inflammation, improved aesthetics and stable occlusion.

**Conclusions.** Comprehensive treatment of patients with advanced periodontitis requires adequate timing and a multidisciplinary approach to eventually restore occlusal harmony with stable periodontium and satisfying aesthetics.

## Key words

periodontitis, orthodontic treatment, non-surgical treatment, comprehensive therapy, pathological tooth migration

## INTRODUCTION

Periodontitis is the sixth most common human disease, estimated to affect 11.2% of the global adult population, and hence representing a significant healthcare, social and economic burden [1]. Periodontitis is a chronic multifactorial inflammatory disease that leads to the loss of supportive tissues around the teeth with gradual deterioration of masticatory function and aesthetics, resulting eventually in the decrease of the life quality [2]. Periodontitis is initiated as a result of dysbiosis and increase in the pathogenicity of Gram-negative bacteria (periopathogens) in the gingival sulcus, which leads to the activation of immune response and destruction of periodontal tissues. A current treatment strategy of periodontitis is based on the reduction of subgingival biofilm that helps to reestablish homeostasis and health. This concept is based on the mechanical subgingival instrumentation, conventionally called scaling and root planning (SRP), combined with proper control of risk factors and home control of bacterial biofilm [3]. However, patients with advanced periodontitis often need additional therapy aimed at occlusal problems resulting from pathologic tooth migration (PTM) and tooth loss. The etiology of PTM appears to be multifactorial; nevertheless, bone loss seems to be a major contributing factor to PTM [4]. Therefore, patients with severe periodontitis, apart from conventional periodontal therapy, require interdisciplinary approach involving close communication and careful coordination among periodontist and orthodontist/prosthodontist.

The case is described of a patient with severe periodontitis and PTM treated by a periodontist and a orthodontist, and 3-year follow-up outcomes of the treatment. A stable periodontal environment, appropriate occlusal relationship and favourable aesthetic results were achieved through interdisciplinary therapy comprising non-surgical periodontal and orthodontic treatment.

Written informed consent was obtained from the patient for the publication of this case report.

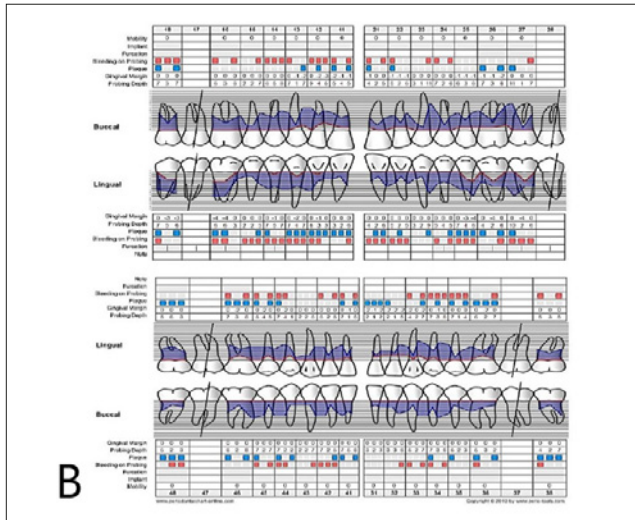
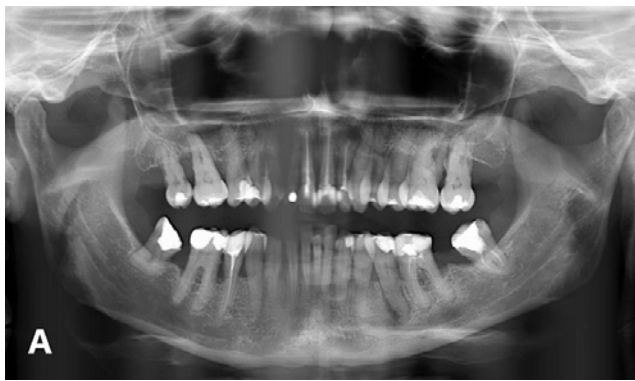## CASE REPORT

A 46-year-old woman sought treatment with the main complaint of the recently changed position of a maxillary anterior tooth. Moreover, bleeding occurred from the gingiva, especially during toothbrushing. The patient reported no systemic diseases and was a non-smoker. Clinical and radiological examination (Fig. 1A, B) revealed generalized severe periodontitis (stage IV, grade C) according to the consensus report classification scheme [5]. Initial bleeding on probing (BOP) score was 54% and full-mouth plaque index (FMPI) was 46%.

Periodontal therapy consists of four phases, starting from initial supra- and subgingival cause-related phases, corrective and supportive phase. The treatment plan should depend on individual needs. In this particular case, the goal of the first phase was to manage with supragingival biofilm as the main risk factor. At the first visit, a full-mouth clinical periodontal examination was performed, and clinical findings correlated with assessment of an orthopantomogram X-ray. Afterwards, the patient was informed about etiology, course and treatment of periodontitis. Subsequently, individual oral

Address for correspondence: Mirella Stańdo-Retecka, Medical University, Pomorska 251, 92-213 Lodz, Poland  
E-mail: mirella.stando@umed.lodz.pl

Received: 06.07.2022; accepted: 10.08.2022; first published: 30.08.2022



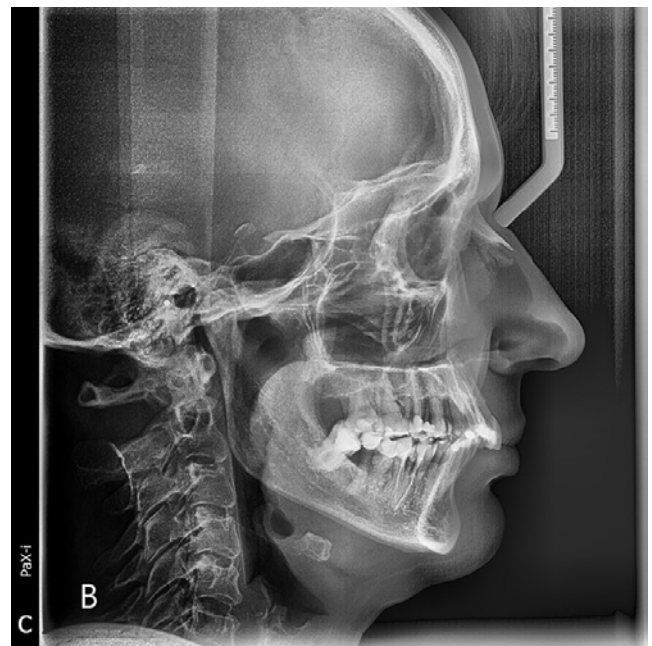
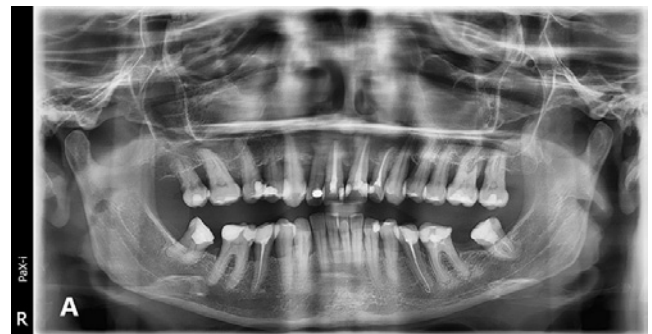**Figure 1.** Orthopantomogram X-ray (A) and full mouth periodontal examination (B)

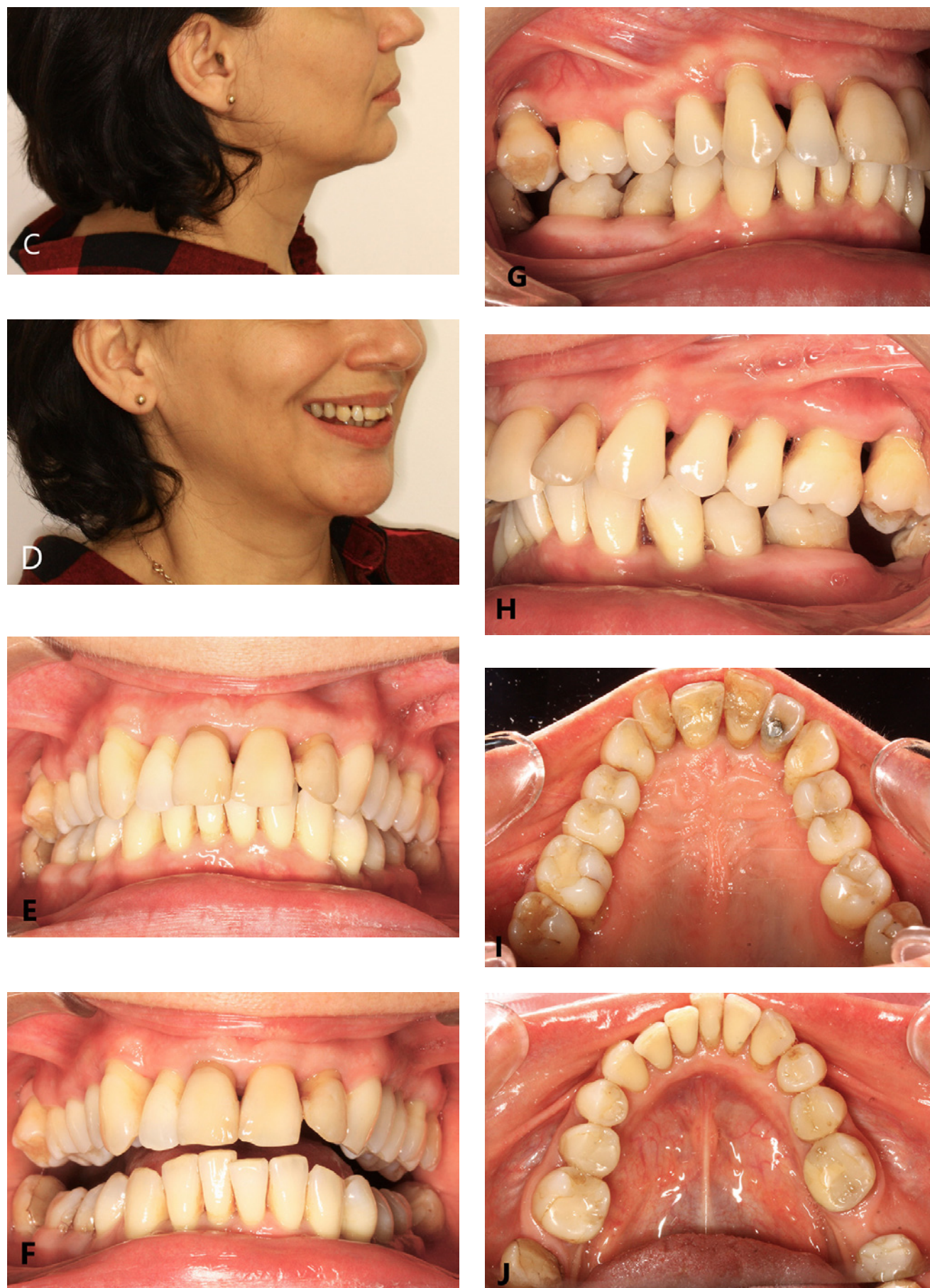hygiene instructions were given, and mechanical plaque removal was performed. Subgingival mechanical plaque removal was performed in quadrants during four sessions using ultrasonic (Piezon Master 700, EMS) and hand (Mini Five Gracey Curette, Hu-Friedy) instrumentation under a local anesthesia, if needed. On the day of the last session of subgingival instrumentation, oral hygiene was evaluated by visualizing plaque with a disclosing agent (HurriView II, Beutlich LP, USA), and toothbrushing technique and the use of interdental toothbrushes was checked and reinforced. An improvement in oral hygiene was demonstrated (FMPI 24 %), and the patient's awareness of the importance of plaque control was high. The efficacy of non-surgical treatment was assessed at week six after completion of subgingival debridement. Clinical examination showed only modest improvement in probing depths (PD) and BOP. Moreover, multiple periodontal abscesses were detected. According to current recommendations, such a case should be retreated with subgingival mechanical therapy, and adjunctive therapy (local/systemic antimicrobial treatment) can be implemented. Thus, full-mouth SRP was performed during a single session, and the patient received Amoxicillin 500 mg and Metronidazole 250 mg three times daily per seven days.

At reevaluation one month later, a major clinical improvement was demonstrated, thus surgical treatment was not needed. At the follow-up three months later, FMSRP was repeated only at the sites with  $PD \geq 4$  mm positive for bleeding on probing. Additionally, endodontic treatment of tooth 35 was performed. One year after the beginning of

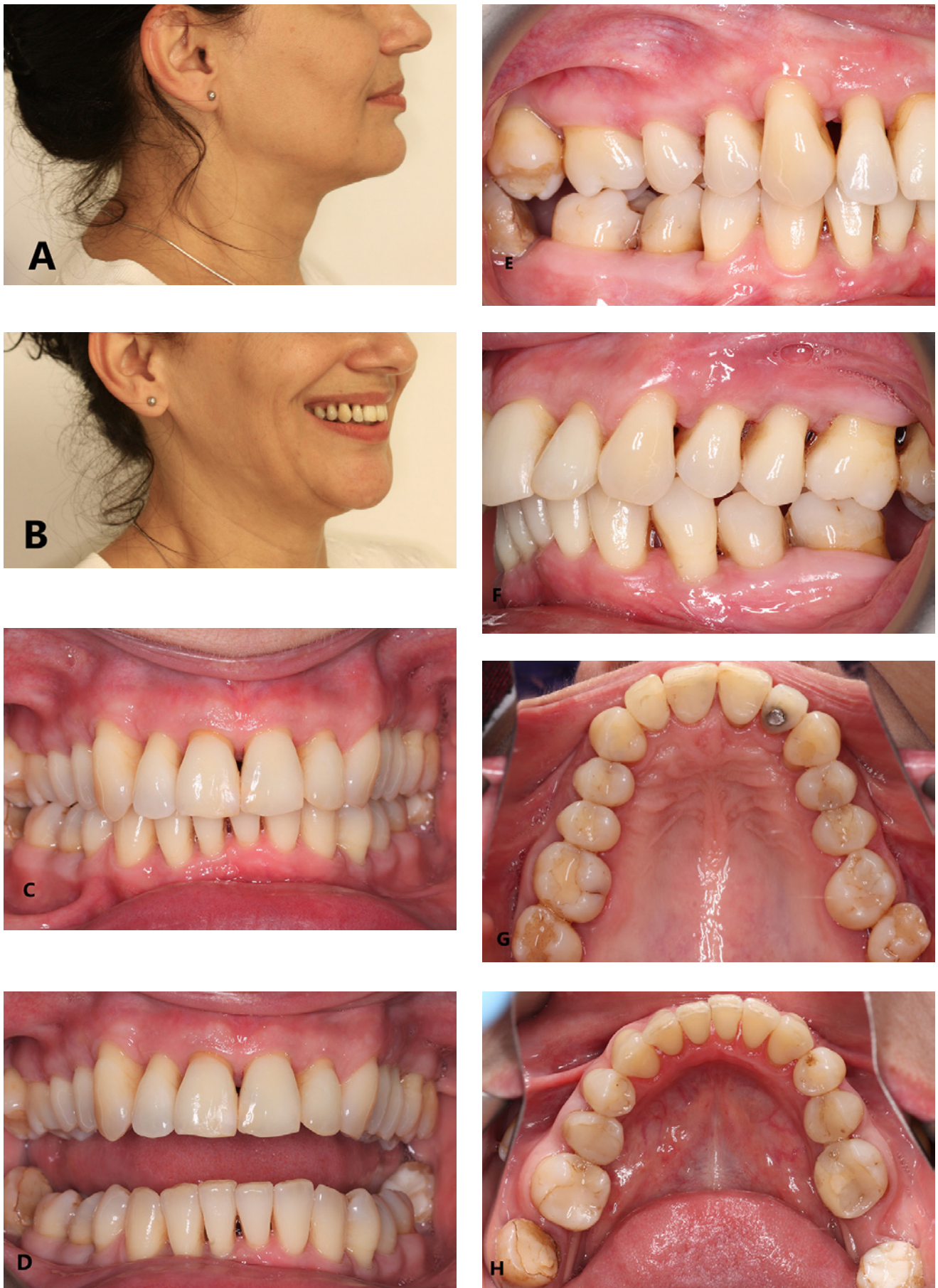
treatment, stabilization of periodontitis was achieved (PD 4 mm or less and no BOP at 4 mm sites, and FMBOP < 10%). FMPI was consequently 7%. At this point, the aesthetic problem of the patient resulting from PTM, especially in the maxilla. Radiological examination was carried out (Fig. 2A, B), together with lateral facial profile (Fig. 2C, D) and intraoral photographs (Fig. 2E-J). The patient was diagnosed with canine and Angle Class II bilaterally with mandibular dental midline shifted to the left side, and accordingly, lateral cephalogram skeletal Class II malocclusion was determined.

Orthodontic therapy was performed by using removable Clear Aligner appliances (Scheu-Dental, Germany) with a three sets of six adjusted thermoplastic aligners, and lasted for five months. Every set consist from doubled three thermoplastic aligners: soft, medium, hard each for maxilla and mandible. The first set of clear aligners was replaced after six weeks from the beginning of orthodontic treatment. Next, the aligners were replaced every eight weeks, and two weeks before the end of the therapy, digital impressions were made to prepare removable retainers. During orthodontic treatment, periodontal maintenance visits were scheduled every two months, and consisted of periodontal examination and professional plaque removal. When orthodontic therapy was finished, lateral facial profile (Fig. 3A, B) and intraoral photographs were taken (Fig. 3C-H). The patient received removable retainers and was asked to wear them 24 hours a day over three months, and later only at night.



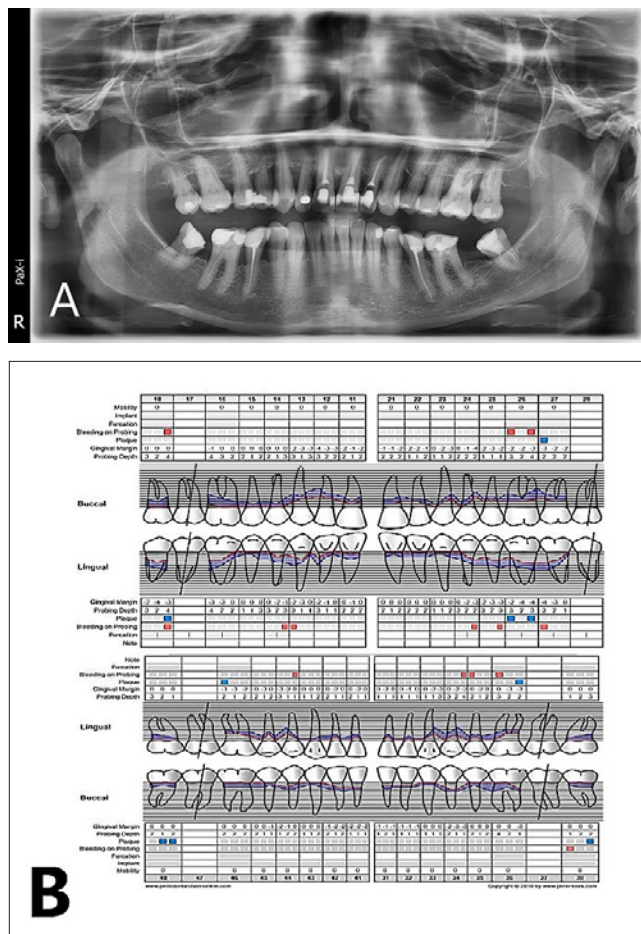


**Figure 2.** Pretreatment orthopantomogram X-ray (A), lateral cephalogram(B), lateral facial profile (C, D), intraoral photographs (E-J).



**Figure 3.** Post-orthodontic treatment lateral facial profile(A,B), intraoral photographs (C-H).

More than three years after comprehensive treatment including non-surgical periodontal and orthodontic therapy, the patient's occlusion and periodontal condition were stable (Fig. 4A,B).



**Figure 4.** Follow-up orthopantomogram X-ray (A) and full mouth periodontal examination (B)

## DISCUSSION

The presented case demonstrated that a patient with advanced periodontitis (stage IV, grade C) and PTM was successfully treated by means of non-surgical therapy followed by orthodontic treatment, with stable results in the 3-year follow-up. However, initial subgingival debridement was not effective, and at the first follow-up visit after six weeks, subgingival instrumentation was supplemented with systemic antibiotics. Due to the good engagement of the patient into the treatment process, satisfying results were gained after one year without periodontal surgery and healthy gingiva on reduced periodontium also achieved.

It is well-known that adherence to medical treatment is one of the issues in the treatment of chronic diseases such as periodontitis. It was demonstrated that nearly 50% of patients failed to adhere to their medical directives, and that 25% of patients were non-adherent to prevention and disease management activities, including taking medication, keeping appointments, screening, exercise, and dietary changes [6]. Subsequently, one year after initial periodontal therapy, when

the stabilization of periodontal tissues was confirmed at the follow-up visits, orthodontic treatment was introduced.

Reduced but healthy periodontium can well tolerate orthodontic tooth movement with no additional treatment-induced attachment loss [7,8]. Moreover, orthodontic correction of pathological mispositioned teeth helps to eliminate occlusal trauma, stabilizes the dentition, and thus improves periodontal status [9,10,11]. It is well recognized that orthodontic treatment is safe in periodontal patients with stabilized periodontitis, but close follow-up is needed during orthodontic therapy to ensure optimal plaque control. Kloukos et al. concluded that long-term prognosis of pathologically-migrated teeth does not seem to be endangered by their orthodontic realignment [12]. Likewise, a clinical study demonstrated that patients with PTM treated orthodontically showed less relapse of periodontal inflammation/migration than patients who received periodontal monotherapy (15% vs. 33%) [13].

Another important issue to consider in the treatment plan of periodontal patients with PTM is timing of the initiation of orthodontic treatment. Papageorgiou et al. in thirty analyzed studies in their review showed that the interval between periodontal and orthodontic treatment varied greatly, ranging from no interval (directly after periodontal treatment) to one year [14]. In this case, orthodontic treatment was introduced one year after the beginning of periodontal treatment, which allowed the achievement of healthy gingiva on reduced periodontium in the patient with initial PD 4.6 mm. The duration of orthodontic treatment in the presented case was relatively short due to mild occlusal problems. Moreover, Papageorgiou et al., in their review of fifteen studies in which the time of therapy was reported, that the mean duration of orthodontic treatment was 14.1 months and range 4.5–20.7 months [14]. Interestingly, an inverse relationship was seen between orthodontic treatment duration and CAL gain in favour of reduced treatment durations, which might implicate that longer treatment provides extended inflammation risk due to the added plaque burden from the orthodontic appliances [15]. It might, therefore, be prudent to take this into account when planning the desired tooth movements and selecting the appropriate orthodontic appliances.

In the presented case, orthodontic treatment was conducted with removable appliances (Clear Aligner, Scheu-Dental, Germany). This choice was made to allow the patient optimal performance of oral hygiene during therapy which is crucial in the management of periodontitis. A recent systematic review and meta-analysis revealed that there is no difference in the treatment results and effect on periodontal tissue when conventional removable orthodontic appliances were compared [14]. Only one small (n = 10) retrospective study showed that conventional braces were found to be more efficient in reducing PD than thermoplastic aligners (PD difference of -1.6 mm), and that study had a high risk of bias [16].

Existing evidence on the effects of orthodontic treatment in patients with severe periodontitis, PTM and intra-bony and furcation defects, is very limited and of poor quality [12, 14]. Patient's compliance, financial issues, as well as the reluctance of orthodontists to treat severe periodontal cases are, among others, the reasons for the limited number of clinical studies in this area. Periodontitis is a chronic disease that requires regular follow-up visits with increasing treatment costs in patients with more progressive forms of periodontitis [17],

thus, not every patient is able to complete a comprehensive treatment plan. Moreover, close communication between periodontist and orthodontist is crucial during all phases of treatment.

## CONCLUSIONS

Depending on the advancement of periodontitis and existing complications, such as pathological tooth migration, occlusal trauma or tooth loss, periodontal patients may require surgical, prosthodontic and orthodontic therapy. Multidisciplinary treatment of periodontitis should lead to the restoration of periodontal health, harmonic occlusion, function and aesthetics to maintain natural dentition long term. Future prospective, long-term clinical studies are warranted to formulate clear clinical recommendations for the orthodontic therapy of periodontally-compromised dentition.

## REFERENCES

- Genco RJ, Sanz M. Clinical and public health implications of periodontal and systemic diseases: An overview. *Periodontol.* 2000. 2020;83:7–13. doi: 10.1111/prd.12344
- Slots J. Periodontitis: facts, fallacies and the future. *Periodontol.* 2000. 2017;75:7–23. doi: 10.1111/prd.12221
- Deas DE, Moritz AJ, Sagun RS Jr, et al. Scaling and root planing vs. conservative surgery in the treatment of chronic periodontitis. *Periodontol* 2000. 2016;71:128–39. doi: 10.1111/prd.12114
- Brunsvold MA. Pathologic tooth migration. *J Periodontol.* 2005;76:859–66. doi: 10.1902/jop.2005.76.6.859
- Papapanou PN, Sanz M, Buduneli N, et al. Periodontitis: consensus report of workgroup 2 of the 2017 World Workshop on the Classification of Periodontal and Peri-Implant Diseases and Conditions. *J Clin Periodontol.* 2018;45:S162–170. doi: 10.1111/jcpe.12946
- Miller TA. Health literacy and adherence to medical treatment in chronic and acute illness: A meta-analysis. *Patient Educ Couns.* 2016; 99: 1079–1086. doi: 10.1016/j.pec.2016.01.020
- Martin C, Celis B, Ambrosio N, et al. Effect of orthodontic therapy in periodontitis and non-periodontitis patients: a systematic review with meta-analysis. *J Clin Periodontol.* 2022;49 Suppl 24:72–101. doi: 10.1111/jcpe.13487
- Antoun JS, Mei L, Gibbs K, et al. Effect of orthodontic treatment on the periodontal tissues. *Periodontol.* 2000. 2017;74(1):140–157. doi: 10.1111/prd.12194
- Xie Y, Zhao Q, Tan Z, et al. Orthodontic treatment in a periodontal patient with pathologic migration of anterior teeth. *Am J Orthod Dentofacial Orthop.* 2014;145(5):685–93. doi: 10.1016/j.ajodo.2013.08.018
- Weston P, Yaziz YA, Moles DR, et al. Occlusal interventions for periodontitis in adults. *Cochrane Database Syst Rev.* 2008;(3):CD004968. doi: 10.1002/14651858.CD004968.pub2. Update in: *Cochrane Database Syst Rev.* 2016;11:CD004968.
- Gkantidis N, Christou P, Topouzelis N. The orthodontic-periodontic interrelationship in integrated treatment challenges: a systematic review. *J Oral Rehabil.* 2010;37:377–90. doi: 10.1111/j.1365-2842.2010.02068.x
- Kloukos D, Rocuzzo A, Stähli A, et al. Effect of combined periodontal and orthodontic treatment of tilted molars and of teeth with intra-bony and furcation defects in stage-IV periodontitis patients: A systematic review. *J Clin Periodontol.* 2021. doi: 10.1111/jcpe.13509
- Zhang J, Zhang AM, Zhang ZM, et al. Efficacy of combined orthodontic-periodontic treatment for patients with periodontitis and its effect on inflammatory cytokines: A comparative study. *Am J Orthod Dentofacial Orthop.* 2017;152:494–500. doi: 10.1016/j.ajodo.2017.01.028
- Papageorgiou SN, Antonoglou GN, Michelogiannakis D, et al. Effect of periodontal-orthodontic treatment of teeth with pathological tooth flaring, drifting, and elongation in patients with severe periodontitis: A systematic review with meta-analysis. *J Clin Periodontol.* 2021. doi: 10.1111/jcpe.13529
- Chhibber A, Agarwal S, Yadav S, et al. Which orthodontic appliance is best for oral hygiene? A randomized clinical trial. *Am J Orthod Dentofacial Orthop.* 2018;153:175–183. doi: 10.1016/j.ajodo.2017.10.009
- Han JY. A comparative study of combined periodontal and orthodontic treatment with fixed appliances and clear aligners in patients with periodontitis. *J Periodontal Implant Sci.* 2015;45:193–204. doi: 10.5051/jpis.2015.45.6.193
- Schwendicke F, Krois J, Engel AS, et al. Long-term periodontitis treatment costs according to the 2018 classification of periodontal diseases. *J Dent.* 2020;99:103417. doi: 10.1016/j.jdent.2020.103417