



A randomized controlled trial evaluating the efficacy and safety of a MYCOFUNGI CREAM in patients with skin mycoses

Roger Ducos Youmsi Fokouo^{1,2,A-F}, Patrick Valere Tsouh Fokou^{1,2,3,A-F}, Grace Choakem^{4,B,F}, Samuel Nhanag^{5,C,F}, Michele Stella Majoumouo^{1,B,F}, Jean-Lucas Tamko^{2,A,F}, Jean Paul Chedjou^{2,4,C-D,F}, Geraldine Kuete^{2,A,F}, Wilfred Fon Mbacham^{6,A,E-F}, Fabrice Fekam Boyom^{1,2,A,E-F}

¹ Antimicrobial and Biocontrol Agents Unit, Faculty of Science, LPMPS, University of Yaounde 1, Yaoundé, Cameroon

² Drug Discovery and Development Research Unit, Laboratoire Roger Ducos, PO Box 20133 Yaounde, Cameroon

³ Department of Biochemistry, Faculty of Science, University of Bamenda, PO Box 39, Bamili, Cameroon

⁴ Elig-Essono Sub-divisional Medical Center, Elig-Essono, Yaounde, Cameroon

⁵ National Multi-sector Program to Combat Maternal, Newborn and Child Mortality (PLMI), Ministry of Public Health, Yaounde, Cameroon

⁶ Laboratory of Public Health Biotechnology, University of Yaoundé 1, Yaounde, Cameroon

A – Research concept and design, B – Collection and/or assembly of data, C – Data analysis and interpretation, D – Writing the article, E – Critical revision of the article, F – Final approval of the article

Youmsi Fokouo RD, Tsouh Fokou PV, Choakem G, Nhanag S, Majoumouo MS, Tamko JL, Chedjou JP, Kuete G, Fon Mbacham W, Fekam Boyom F. A randomized controlled trial evaluating the efficacy and safety of a MYCOFUNGI CREAM in patients with skin mycoses. *J Pre-Clin Clin Res.* 2022; 16(2): 27–33. doi: 10.2644/jpccr/150030

Abstract

Introduction and Objective. Skin mycoses is a neglected condition with low quality of life and morbidity that primarily affects school-aged children in developing nations. Current treatment options have considerable limits, emphasizing the critical need for alternative therapies. The purpose of this clinical trial was to evaluate the potential benefit of Mycofungi cream in individuals with superficial fungal skin infection disorders.

Materials and method. Patients with cutaneous mycoses ranging in age from 2–65 years were randomly assigned to either Mycofungi (*Syzygium aromaticum* (L.) Merr.) cream or Terbinafine creams. Within a four-week follow-up, the rates of cure or improvement were compared between the two groups. An incidental side-effect was also noted.

Results. A total of 256 individuals with skin mycoses were preliminarily screened, and 80 eligible participants enrolled and randomly assigned to the Mycofungi (n=40) or Terbinafine (n=40) groups. Overall, 92.5% (37/40) of patients with cutaneous mycoses were asymptomatic or had improved condition following Mycofungi application at the final follow-up appointment. After four weeks of treatment, the clinical cure rate was high and nearly identical in the two groups: 80% in the Mycofungi group and 85% in the Terbinafine group. Both terbinafine and mycofungi were well tolerated.

Conclusions. The efficacy of Mycofungi cream (*S. aromaticum*) in treating or reducing the severity of skin mycoses was proven in this clinical trial. Nonetheless, additional detailed experiments are needed to reach a conclusion on the efficacy of Mycofungi.

Key words

clinical trial, *Syzygium aromaticum*, mycofungi, skin mycoses

INTRODUCTION

Skin mycoses are Skin Neglected Tropical Diseases [1] characterized by lesions of the nails, scalp, and skin [2, 3]. Although fungi are part of the commensal skin microbiota, various species can cause illnesses that are often recurrent or chronic. Skin mycoses affect 20–25% of the world population [4]. Causative agents include yeasts, with *Candida* species being the most prevalent and dermatophytes [4, 5]. *Candida*, *Cryptococcus*, *Malassezia*, and *Rhodotorula*, species are skin commensals, but can also become pathogenic [4]. Skin candidiasis is an acute or chronic, superficial or deep

infection with a very wide clinical spectrum. It is mainly found in patients with compromised host defences or skin flora [6, 7]. *Malassezia* species are lipophilic yeasts, which are part skin microbiome. *Malassezia* species can cause diseases such as *Malassezia* folliculitis, head and neck dermatitis, seborrheic dermatitis, and pityriasis versicolor [8–10]. Pityriasis versicolor is a benign and frequent infection reported worldwide with more than 50% prevalence in tropical countries. It is characterized by hyperpigmented or hypopigmented finely scaly macules [11]. Besides, dermatophytes are filamentous fungi, Epidermophyton, Microsporum, and Trichophyton characterized by partitioned mycelium and spore production. Trichophyton rubrum is the main causative agent of superficial dermatophytosis worldwide. *T. violaceum* is predominantly diagnosed in Northern and Eastern Africa while *M. audouinii* and *T. soudanense* are mainly encounter in Central and West Africa

Address for correspondence: Patrick Valere Tsouh Fokou, PhD; Department of Biochemistry, Faculty of Science, University of Bamenda, PO Box 39, Bamili, Cameroon
E-mail: ptsouh@gmail.com

Received: 17.02.2022; accepted 11.05. 2022; first published: 27.05.2022

[12]. Dermatophytes attack mainly the epidermal stratum corneum and the integuments, at the expense of keratin, and are generally distributed in a ubiquitous manner [13, 14]. Clinically, dermatophytes cause cutaneous-phanerial pathologies called dermatophytosis, mainly manifested by damage to the skin (circine epidermophytia, intertrigo), scalp (clipping ringworms, inflammatory ringworms, Tinea capitis, favic ringworms), nails (Onychomycosis or onyxis) and hair (folliculitis, sycosis) [15]. Many reports emphasize the heavy burden of dermatophytosis in Africa with a prevalence of 10% to more than 70%. Tinea capitis is the primary clinical presentation of dermatophytosis in African children while tinea corporis is mainly found in African adults [12].

Overall, the incidence of fungal infections has increased tremendously in the last few decades due to the extensive application of broad-spectrum antibiotics, immunosuppressive agents and medical implant devices [16]. Mycotic infections disease has therefore become a serious public health problem with a high rate of affected people.

Frontline treatment of skin mycoses includes polyenes (Amphotericin B, Nystatin), azoles (Clotrimazole, Isoconazole, Itraconazole, Fluconazole, Tioconazole, Voriconazole), echinocandins (Anidulafungin, Caspofungin, Micafungin), and topical allylamines (Terbinafine, Naftifine) [17–20]. However, drawbacks such as toxicity, emergence of drug resistance and complex drug interactions, jeopardize the effectiveness of these drugs [19–24]. Therefore, new, innocuous and more effective antifungal agents should be developed urgently.

Preliminary work shows the anti-dermatophyte, anticandidal and antimould potency of *Syzygium aromaticum* [25–29]. *Syzygium aromaticum*-based cream (Mycofungi cream) further showed efficacy and safety in a guinea pig model [30] warranting clinical validation.

Therefore, the present study aimed at the clinically evaluated health benefit of Mycofungi cream in cutaneous fungal infections.

MATERIALS AND METHOD

Description of the herbal drug Mycofungi. This is an herbal medicinal product used by the population to treat fungal infections of the skin, scalp and nails. It is presented in the form of whitish cream in 100g tube manufactured by Laboratoire Roger Ducos, a local Cameroonian company which develops some cosmetic and category 2 pharmaceutical products according to the WHO phytomedicines classification. Mycofungi was prepared using *Syzygium aromaticum* cloves in accordance with pharmaceutical formulation standard preparation procedures.

Ethical considerations. The protocol was reviewed and approved by the Cameroon National Ethics Committee (Ref. No. 2016/11/842/CE/CNERSH/SP) and participating centre (CMA Elig-Essono). The study was conducted in accordance with the Declaration of Helsinki and good clinical practice guidelines. Written informed consent was given by the patients, or by a parent/guardian in the case of minor patients, prior to entering the study.

Study design and areas. The study consisted of a zero-phase randomized, single-blind clinical trial in patients

with skin fungal infections to evaluate the clinical benefit of Mycofungi versus Lamisil (Terbinafine). It was conducted from April 2017 – April 2018. All activities were performed at the Elig-Essono Sub-divisional Medical Center, Elig-Essono, Yaounde, Cameroon. No changes occurred in methods after trial commencement.

Inclusion criteria. The following inclusion criteria were adopted: male and female gender; aged 3 – 62 years; presenting classic signs and symptoms of superficial mycosis, such as pruritis, fever, pustules, burn sensation, pain, erythema, purpura, angiomas, vesicles, pustules, papule, nodules, vegetation, squamous, atrophy, cruste, erythemato-squamous, sclerosis, erosion, ulcerations, fissure and lichenification, as ascertain by a dermatologist; being able and willing to follow the protocol and attend the study's scheduled visits for the duration of the trial, as well as signing an informed consent form. The informed consent form for underage participants was signed by a parent/guardian.

Exclusion criteria. The following exclusion criteria were adopted: serious intercurrent illness, fatigue, any situation that could significantly interfere with compliance with the study, including all the prescribed assessments and follow-ups, pregnancy, lactation, significant surgical or medical disorders, or recent history of using antifungals.

Participants and enrollment. On admission, patients were fully examined by the dermatologist for skin mycosis. Those patients who fulfilled the inclusion criteria and signed the informed consent form were enrolled. The enrolled volunteers were randomized into two treatment groups.

Treatments and follow-up. Patients were arbitrarily allocated to receive either Mycofungi cream as the intervention group, or Terbinafine cream as the control group. The maximum dose per application was limited to 5 g per day, as long as it covered less than 30% of the body surface area. Patients were asked to apply a suitable quantity of treatment cream on skin lesions once daily throughout the four-weeks study. In the control group, patients received Terbinafine (Lamisil) cream which was similar to the Mycofungi cream prescription. Participants who did not use a minimum of 70% of the cream during the trial period were intolerant to the drug. The patients were consulted at the beginning, and after 1, 2, 3 and 4 weeks of the study period; their symptoms were assessed in terms of frequency and severity on a scale of symptoms of disease progression. Patients or parents of patients participating in the trial also received frequent telephone calls to check on their health status. The phone calls represented a follow-up and retention programme, designed to minimize the number of participants opting-out prematurely. Concomitant application of the study treatment and other medications to the same area was prohibited.

Outcome estimation. The primary outcomes in this trial were estimated as changes in the frequency and severity of symptoms. The absence of clinical signs of superficial fungal infection in patients at the end of the four weeks treatment indicated an efficacy of the product. The estimation of clinical signs were measured as (1) cure (complete resorption of signs and symptoms), (2) improved (considerable resolution of signs and symptoms), and (3) failure (no improvement).

Patients were monitored for any relapse one week after treatment and patient-reported adverse events.

Safety assessment. Adverse events were defined as either a new event emerging after administration of the trial drug, or any previous event that increased in severity following drug administration. They were monitored throughout the treatment period until the follow-up visit (defined as 28 days after the last dose of study drug) during the weekly follow-up visits with a dermatologist. All patients were asked to report any drug side-effects.

Statistical methods. Data were summarized as mean or as a percentage. Chi-square test was used for statistical comparisons of qualitative baseline characteristics, such as age and gender, and baseline status with a level of significance of 5%.

RESULTS

Patients enrollment. From April 2017 – April 2018, 256 patients were assessed for eligibility. Eighty consenting patients who met inclusion criteria were assigned into two groups of forty patients each. No loss to follow-up was recorded in either group. Fig. 1 shows the flowchart of the groups' recruitment, distribution, intervention, follow-up, and analysis.

Baseline clinical characteristics. The mean age of participants in the Mycofungi and Terbinafine groups was (26.85 ± 13.38) and (23.58 ± 16.47) years, respectively. The most representative age group was between 22–41 years for the two groups (42 over 80 patients with 24 from Mycofungi group and 18 from control group). The ages range of participants were not statistically different between the two groups ($P=0.9758$).

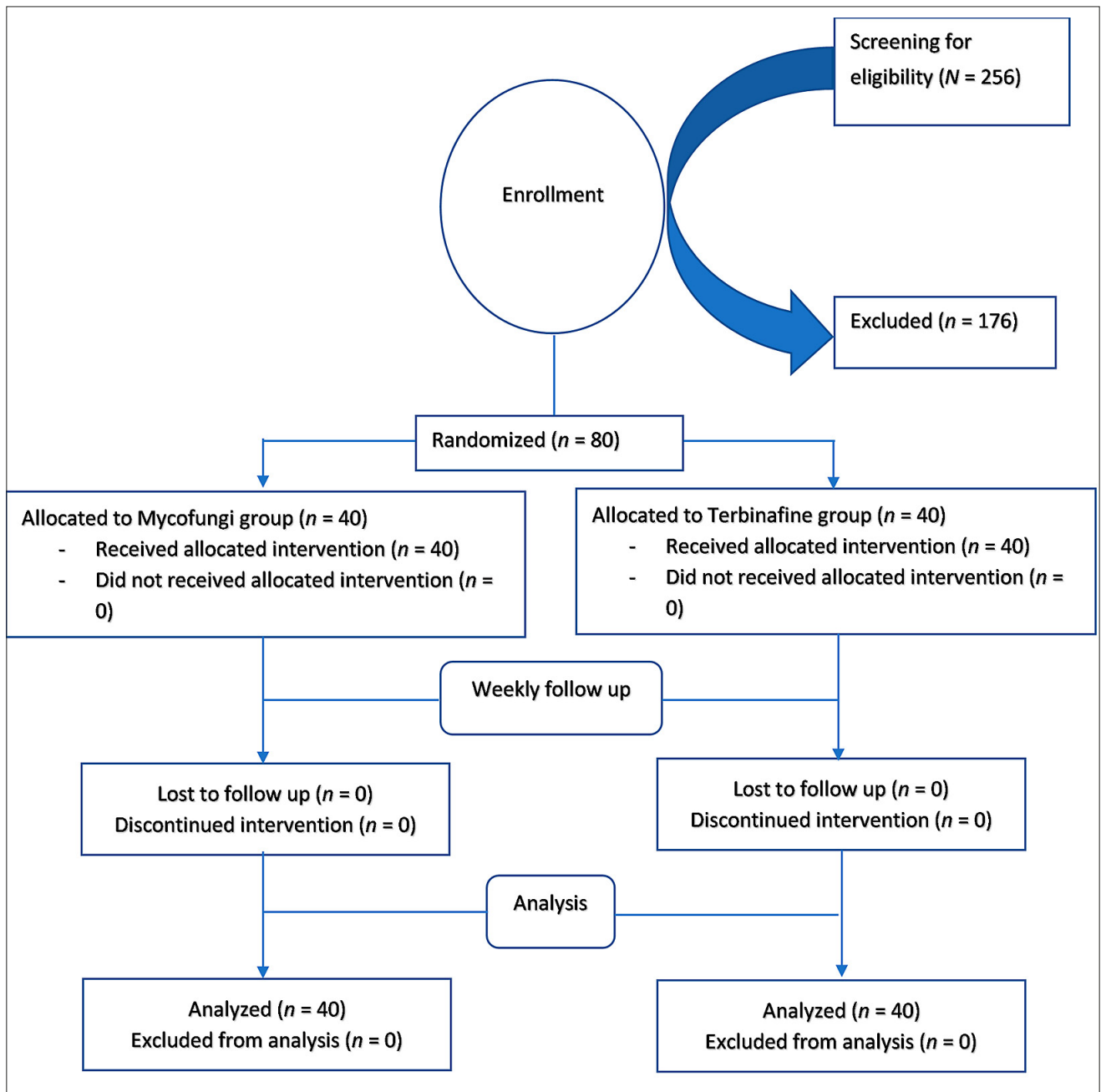


Figure 1. Flow diagram of patient recruitment and randomized to Mycofungi or placebo

Females predominated in the Mycofungi group with 21 patients against 19 males, as well as in Terbinafine group with 26 females against 14 males, but the difference was not statistically significant ($P=0.256 > 0.05$). Additional demographic information of the participants are presented in Table 1. The majority of parameters in baseline clinical characteristics between the two groups were not significantly differences (Tab. 1; $P > 0.05$).

Table 1. Profile of patients treated with Terbinafine or Mycofungi

Characteristics	Mycofungi	Terbinafine	Chi square test (P value)	
Evaluable patients (n)	40	40		
Gender	Female	21	0.256	
	Male	19		
Mean age (year)	26.85 ± 13.38	23.57 ± 16.47	0.9758	
Age range (years)	2-21	12	16	
	22-41	24		
	>42	4		
Baseline sign/symptom (Clinical aspect)				
Baseline sign/symptom	Pruritis (n)	32	0.363	
	Fever (n)	3		
	Pustules (n)	0		
	Burn sensation (n)	8		
Duration of symptoms/lesion	Pain (n)	22	0.061	
	≤4 weeks (n)	13		
Previous treatment	> 4 weeks (n)	27	27	
	Receiving antibiotics (n)	27		
	Receiving antivirals (n)	2		
	Receiving corticosteroids (n)	2		
	Receiving antihistaminic (n)	2		
	Receiving antipyretics (n)	23		
	Receiving antifungal (n)	26		
	Receiving antidiabetic (n)	1		
Medical history	Receiving antimalarial (n)	1	0.556	
	Receiving other	1		
	Use of depigmenting agents (n)	6		
	Obesity (n)	1		
	Diabetes (n)	1		
Description of skin lesions	HIV (n)	2	1.000	
	Scabies (n)	0		
	Scabies (n)	3		
	Scabies (n)	0		
Lesion site	Scalp (n)	9	9	1.000

Pruritis and pain were the major symptoms encountered in the Mycofungi and Terbinafine groups with 32 and 35; 22 and 30 occurrences, respectively. The majority of symptoms lasted more than four weeks and most of the patients previously received antibiotherapy. The diagnosis reveals 20 patients suffering from Pityriasis versicolor with 10 in each group, 21 patients had dermatophytosis of the glabrous skin (11 in the Mycofungi group and 10 in the Terbinafine group), six

Characteristics	Mycofungi	Terbinafine	Chi square test (P value)
Large skin folds (n)	1	6	0.048
Minor skin folds (n)	3	4	0.692
Nails (n)	6	6	1.000
Hands (n)	3	5	0.456
Feet (n)	3	5	0.456
Interdigitopalmary (n)	1	0	0.314
Interdigital Plantar (n)	4	4	1.000
Anterior trunk(n)	11	9	0.606
Posterior trunk (n)	13	10	0.459
Buttocks area (n)	9	12	0.446
Primary lesion	Erythema (n)	27	0.066
	Purpura (n)	6	
	Angiomas (n)	0	
	Vesicles (n)	24	
	Pustules (n)	1	
	Bulles (n)	0	
	Papule (n)	0	
	Nodules (n)	4	
	Vegetation (n)	1	
	Vegetation (n)	0	
Secondary lesion	Squames (n)	23	0.491
	Atrophy (n)	8	
	Cruste (n)	23	
	Erythemato-squamous (n)	34	
	Sclerosis (n)	1	
	Erosion (n)	1	
	Ulcerations (n)	0	
	Fissure (n)	5	
	Lichenification (n)	1	
	Lichenification (n)	1	
Overall clinical diagnosis			
Pityriasis versicolor (n)	10	10	0.974
Dermatophytosis of the glabrous skin (n)	11	10	0.974
Perionyxis (n)	2	4	0.974
Tinea capitis (n)	8	9	0.974
Intertrigo (n)	3	3	0.974
Onychomycoses (n)	2	2	0.974
Nappy rash (n)	4	2	0.974

(n) - frequency of age, gender and baseline status, and clinical diagnosis. * Chi-square test was used for statistical comparisons with a level of significance of 5%.

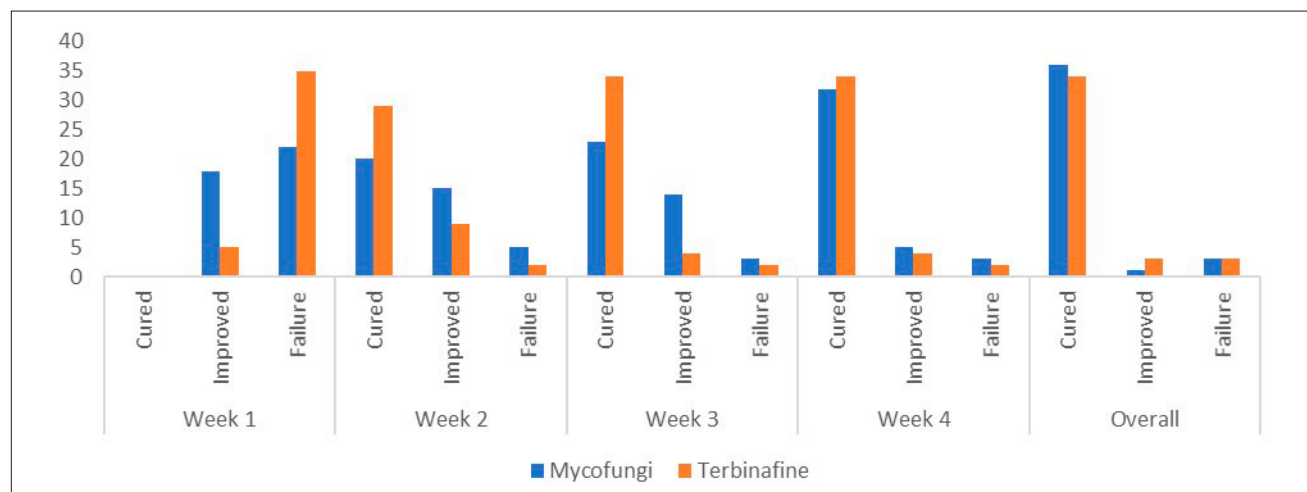


Figure 2. Efficacy Evaluation of the Mycofungi and Terbinafine Treatments over the weeks

patients had perionyxes (two in the Mycofungi group and four in the Terbinafine group), 17 had Tinea capitis (eight in the Mycofungi group and nine in the Terbinafine group), six had intertrigo (three in each group), four had onychomycosis (two in each group) and six patients had nappy rash (four in the Mycofungi group and two in the Terbinafine group) (Tab. 1).

Clinical response. Within-group changes in severity of symptoms in both groups were significantly lessened after intervention ($P > 0.05$). Severity of symptoms were significantly reduced in both groups (Fig. 2, Tab. 2). Repeated measures logistic regression analysis showed that over the course of the study, both treatments induced significant reduction in severity ($P < 0.05$). The clinical success rates were similar in the two treatment groups, and of the 80 evaluable

patients who received both treatments, none was cured or asymptomatic at the first follow-up visit (after one week).

For patients who received Mycofungi cream, 18 (45%) were improved and 22 (55%) failed treatment at first follow up visit. At the second visit, 20 patients (50%) were cured, 15 (37.5%) patients improved, and five patients (12.5%) failed treatment. At the third visit, a total of 23 patients (57.5%) were cured, 14 patients (35%) improved, and three patients (7.5%) failed treatment. The clinical cure rate in the Mycofungi group was 80% (32/40) at the final follow-up visit. Five patients were clinically improved and three patients had a recurrence. Overall, at the final follow-up visit, 92.5 % (37/40) were asymptomatic or improved.

In the group receiving Terbinafine, only five of 40 patients (12.5%) were clinically improved and 35 of 40 patients (87.5%)

Table 2. Frequency of absence of symptoms on days 7, 14, 21 and 28 in the Terbinafine/Mycofungi cream groups upon treatment

Skin mycoses	Outcome	Day 7		Day 14		Day 21		Day 28		Last visit	
		MYC	TER	MYC	TER	MYC	TER	MYC	TER	MYC	TER
Pityriasis versicolor (n)	Cured	0	0	6	6	7	9	9	9	10	9
	Improved	2	2	4	4	3	1	1	1	0	1
	Failure	8	8	0	0	0	0	0	0	0	0
Dermatophytosis of glabrous skin (n)	Cured	0	0	3	6	5	9	9	9	10	9
	Improved	4	1	8	3	6	0	2	0	1	0
	Failure	7	9	0	1	0	1	0	1	0	1
Perionyxis (n)	Cured	0	0	1	4	1	3	1	3	1	3
	Improved	1	0	0	0	0	1	0	1	0	1
	Failure	1	4	1	0	1	0	1	0	1	0
Tinea capitis (n)	Cured	0	0	6	9	6	9	7	9	8	9
	Improved	6	1	2	0	2	0	1	0	0	0
	Failure	2	8	0	0	0	0	0	0	0	0
Intertrigo (n)	Cured	0	0	2	2	2	2	3	2	3	2
	Improved	2	1	0	0	1	0	0	0	0	0
	Failure	1	2	1	1	0	1	0	1	0	1
Onychomycosis (n)	Cured	0	0	0	0	0	0	1	0	1	0
	Improved	0	0	0	2	1	2	0	2	0	1
	Failure	2	2	2	0	1	0	1	0	1	1
Nappy rash (n)	Cured	0	0	2	2	2	2	2	2	3	2
	Improved	3	0	1	0	1	0	1	0	0	0
	Failure	1	2	1	0	1	0	1	0	1	0
Summary	Cured	0	0	20	29	23	34	32	34	36	34
	Improved	18	5	15	9	14	4	5	4	1	3
	Failure	22	35	5	2	3	2	3	2	3	3

(n) - frequency

failed treatment by the first follow-up visit. By the second visit, 29 (72.5%) were cured, nine (22.5%) improved, and two (5%) failed treatment. At the third and fourth visits, 34 (85%) were cured, four patients (10%) were improved and two (5%) did not respond to treatment. At the final follow-up visit, 95% (38/40) were asymptomatic or improved (Fig. 3). The recurrence rates in both treatment groups were not statistically different (Tab. 2).

In the light of the findings, within the first two weeks Terbinafine portrayed higher cured rate of efficacy compared to Mycofungi, this pattern continued until the third week when Terbinafine showed superiority in the cured rate with 34 versus 23 for Mycofungi. However, Terbinafine's efficacy did not improve after the third week, whereas that of Mycofungi continued to progress to reach comparable effectiveness with Terbinafine by the fourth week (Fig. 2). This suggests a delayed action of Mycofungi.

With the exception of perionyxes, onychomycosis and nappy rash which recorded one treatment failure each, all skin mycoses were cured or improved by Mycofungi cream, similarly to the Terbinafine group.

Adverse effects. Overall, a favourable 95% (38/40) response was attained for patients who received Mycofungi. Apart from two patients who reported residual nappy rash and contact irritant dermatitis, no adverse effects from the interventions were reported by patients. Lastly, one patient keen for depigmentation or bleaching was recorded, suggesting an allergy reaction probably linked to an interaction between Mycofungi and the bleaching agent. However, allergic contact sensitivity to commonly used antifungal drugs such as miconazole, econazole, tioconazole and isoconazole, has been previously reported [31].

DISCUSSION

The study evaluated the safety and efficacy of Mycofungi in mitigating skin mycosis symptoms via a randomized, Terbinafine-controlled clinical trial. Mycofungi like Terbinafine was found to significantly reduce severity in skin mycosis. This finding is particularly important when considering the superiority of Terbinafine versus a number of medications used for the management of superficial mycosis. Given that the reduction in symptoms in the Mycofungi group was close to 90%, this effect is clinically significant. Although animal and experimental studies have been conducted on Mycofungi, only the present study have demonstrated its clinical efficacy. A herbal combination drops containing *S. aromaticum* exhibited good efficacy in reducing the burden of skin infection as well as acute external otitis symptoms [32]. *S. aromaticum* cloves are spices consisting in a mixture of phytochemicals, such as phenolic acids, flavonol glucosides, tannins and phenolic volatile oils (eugenol, acetyl eugenol), endowed with multiple medicinal benefits including strong antioxidant, carminative, anti-inflammatory, anti-nausea, anti-vomiting, anti-proliferative, mouth freshening, antibacterial, antifungal, analgesic, antiseptic and sedative effects that represent a significant therapeutic added value [32, 33].

Although a randomized controlled trial protocol was adopted in the present study, there were limitations such as the small sample size, which should be further increased for a consistent interpretation of the obtained results.

CONCLUSION

This randomized Terbinafine-controlled clinical trial demonstrated the efficacy of Mycofungi cream (*S. aromaticum*) to treat or reduce severity of skin mycosis.

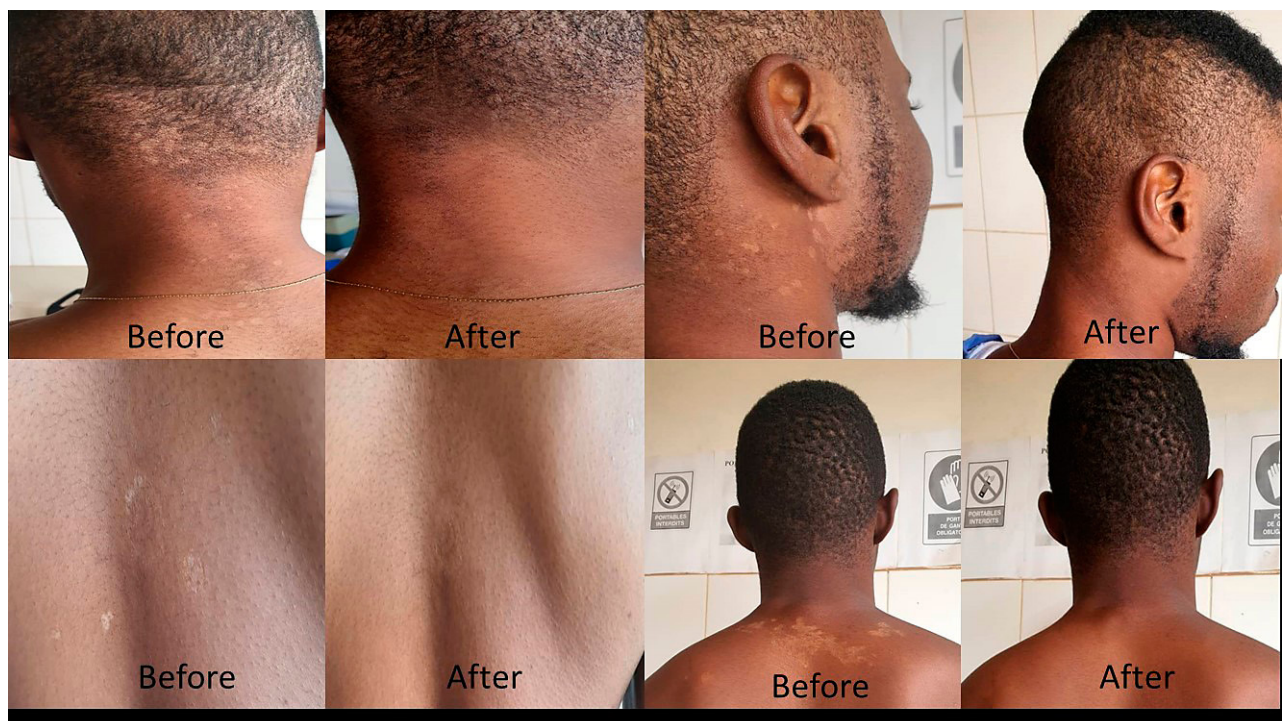

Figure 3. Sample photos of before and after treatment of Pityriasis versicolor with Mycofungi therapy

Nevertheless, a larger-scale qualified methodological trial of longer duration of the interventions are needed to replicate and expand the preliminary findings. This planned study will enable a large-scale validation of the Mycofungi herbal treatment in managing symptoms of fungal skin diseases.

Acknowledgements

The authors thank all participants for their cooperation. We also thank Dr Bita Gertrude, the then Director of the Elig-Essono Sub-divisional Medical Center, Yaounde, Cameroon, for granting authorization to conduct the study.

REFERENCES

1. WHO. Recognizing neglected tropical diseases through changes on the skin A training guide for front-line health workers. Control of Neglected Tropical Diseases. WHO/HTM/NTD/2018.03 ed. Geneva, 2018, p. 48.
2. Hay RJ, Asiedu K. Skin-Related Neglected Tropical Diseases (Skin NTDs) – a new challenge. *Trop Med Infect Dis.* 2018; 4(1): 4.
3. de Macedo PM, Freitas DFS. Superficial Infections of the skin and nails. In: Zaragoza O, Casadevall A, editors. *Encyclopedia of Mycology.* Ed. 1. Elsevier; 2021. p. 707–718.
4. Kühbacher A, Burger-Kentischer A, Rupp S. Interaction of Candida Species with the skin. *Microorganisms.* 2017; 5(2): 32.
5. Praver S, Praver S, Bershow A. Superficial Fungal Infections. In: Soutor C, Hordinsky MK, editors. *Clinical Dermatology.* Ed. 1. McGraw Hill; 2013. p. 71.
6. Kwon-Chung KJ, Bennett JE. Medical mycology. *Rev Inst Med Trop Sao Paulo.* 1992; 34(6): 504–504.
7. Capoci IRG, Sakita KM, Faria DR, et al. Two New 1,3,4-Oxadiazoles with effective antifungal activity against *Candida albicans*. *Front Microbiol.* 2019; 10: 2130–2130.
8. Saunte DML, Gaitanis G, Hay RJ. Malassezia-associated skin diseases, the use of diagnostics and treatment. *Front Cell Infect Microbiol.* 2020; 10: 112–112.
9. Vlachos C, Henning MAS, Gaitanis G, et al. Critical synthesis of available data in Malassezia folliculitis and a systematic review of treatments. *J Eur Acad Dermatol Venereol.* 2020; 34(8): 1672–1683.
10. Thayikkannu AB, Kindo AJ, Veerarahavan M. Malassezia-Can it be Ignored? *Indian J Dermatol.* 2015; 60(4): 332–339.
11. Karray M, McKinney WP. Tinea Versicolor. [Updated 2021 Aug 11]. In: StatPearls [Internet]. Treasure Island (FL): StatPearls Publishing; 2022 Jan-. Available from: <https://www.ncbi.nlm.nih.gov/books/NBK482500/>
12. Coulbaly O, L'Ollivier C, Piarroux R, et al. Epidemiology of human dermatophytoses in Africa. *Med Mycol.* 2018; 56(2): 145–161.
13. Abd Elmegeed ASM, Ouf SA, Moussa TAA, et al. Dermatophytes and other associated fungi in patients attending to some hospitals in Egypt. *Braz J Microbiol.* 2015; 46(3): 799–805.
14. Didehdar M, Shokohi T, Khansarinejad B, et al. Characterization of clinically important dermatophytes in North of Iran using PCR-RFLP on ITS region. *J Mycol Med.* 2016; 26(4): 345–350.
15. Ganne A. Les mycoses superficielles a l'officine: description clinique, traitement et prevention. Limoges: Universite de Limoges; 2012.
16. Gong Y, Liu W, Huang X, et al. Antifungal activity and potential mechanism of n-butylphthalide alone and in combination with fluconazole against *Candida albicans*. *Front Microbiol.* 2019; 10(1461): 1461.
17. Verma S, Heffernan MP. Superficial fungal infections: dermatophytosis, onychomycosis, tinea nigra, piedra. In: Wolff K, Goldsmith LA, Katz SI, Gilchrist BA, Paller AS, Leffell DJ, editors. *Fitzpatrick's dermatology in general medicine.* Ed. 7. McGraw-Hill; 2008. p. 1807–1821.
18. Hay RJ, Ashbee HR. Superficial mycoses. In: Burns T BS, Cox N, Griffiths C, editor. *Rook's Textbook of Dermatology.* Ed. 8 Wiley-Blackwell; 2010. p. 36.5–36.68.
19. Dias MF, Bernardes-Filho F, Quaresma-Santos MV, et al. Treatment of superficial mycoses: review. Part II. *An Bras Dermatol.* 2013; 88(6): 937–944.
20. McKenney PT, Nessel TA, Zito PM. Antifungal Antibiotics. [Updated 2021 Nov 15]. In: StatPearls [Internet]. Treasure Island (FL): StatPearls Publishing; 2022 Jan-. Available from: <https://www.ncbi.nlm.nih.gov/books/NBK538168/>
21. Pfaller MA, Diekema DJ. Epidemiology of invasive mycoses in North America. *Crit Rev Microbiol.* 2010; 36(1): 1–53.
22. da Matta DA, Souza ACR, Colombo AL. Revisiting Species Distribution and Antifungal Susceptibility of *Candida* Bloodstream Isolates from Latin American Medical Centers. *J Fungi (Basel).* 2017; 3(2): 24.
23. Sanguinetti M, Posteraro B, Lass-Flörl C. Antifungal drug resistance among *Candida* species: mechanisms and clinical impact. *Mycoses.* 2015; 58: 2–13.
24. Vandeputte P, Ferrari S, Coste AT. Antifungal resistance and new strategies to control fungal infections. *Int J Microbiol.* 2012; 2012: 713687.
25. Al-Bader SM, Moqbel FS. Effect of Selected Plant Extracts on *Malssezia Furfur* in Culture. *Eurasian J Sci Eng.* 2017;3 (special):43.
26. Fokouo RDY, Fokou PVT, Mbouna CDJ, et al. Antidermatophyte activity of *Syzygium aromaticum*, *Petroselinum crispum*, and *Tetrapleura tetraaptera*. *Biomed Biotechnol Res J.* 2020; 4(1): 55.
27. Pinto E, Vale-Silva L, Cavaleiro C, et al. Antifungal activity of the clove essential oil from *Syzygium aromaticum* on *Candida*, *Aspergillus* and dermatophyte species. *J Med Microbiol.* 2009; 58(Pt 11): 1454–1462.
28. Rana IS, Rana AS, Rajak RC. Evaluation of antifungal activity in essential oil of the *Syzygium aromaticum* (L.) by extraction, purification and analysis of its main component eugenol. *Braz J Microbiol.* 2011; 42: 1269–1277.
29. Yassin MT, Mostafa AA-F, Al-Askar AA. In vitro anticandidal potency of *Syzygium aromaticum* (clove) extracts against vaginal candidiasis. *BMC Complement Med Ther.* 2020; 20(1): 25.
30. Fokouo RDY, Fokou PVT, Mbouna CDJ, et al. Formulation and evaluation of safety and antifungal efficacy of *Syzygium aromaticum*-base cream on Guinea pigs infected with *Trichophyton mentagrophytes*. *Pharmacog J.* 2020; 12(2).
31. Abhinav C, Mahajan VK, Mehta KS, et al. Allergic contact dermatitis due to clotrimazole with cross-reaction to miconazole. *Indian J Dermatol Venereol Leprol.* 2015; 81(1): 80–82.
32. Panahi Y, Akhavan A, Sahebkar A, et al. Investigation of the effectiveness of *Syzygium aromaticum*, *Lavandula angustifolia* and *Geranium robertianum* essential oils in the treatment of acute external otitis: A comparative trial with ciprofloxacin. *J Microbiol Immunol Infect.* 2014; 47(3): 211–216.
33. Kubatka P, Uramova S, Kello M, et al. Antineoplastic effects of clove buds (*Syzygium aromaticum* L.) in the model of breast carcinoma. *J Cell Mol Med.* 2017; 21(11): 2837–2851.